Journal of Cardiology Cases 26 (2022) 375–378

Contents lists available at ScienceDirect

Journal of Cardiology Cases

journal homepage: www.elsevier.com/locate/jccase

Case Report

Chronic expanding intrapericardial hematoma associated with blunt chest trauma 50 years earlier

Shuhei Nishijima (MD), Yoshitsugu Nakamura (PhD) *, Yuto Yasumoto (MD), Takuya Narita (PhD)

Department of Cardiovascular Surgery, Chiba-nishi General Hospital, Matsudo, Chiba, Japan

ARTICLE INFO

Article history:
Received 10 February 2022
Received in revised form 22 July 2022
Accepted 30 July 2022

Keywords:
Intrapericardial hematoma
Constrictive pericarditis
Cardiac computed tomography
Case report

ABSTRACT

Chronic expanding intrapericardial hematoma can be treated surgically; however, a correct diagnosis is not always established, thus the condition remains untreated. A 76-year-old man was referred to us with a diagnosis of congestive heart failure. The patient had experienced blunt trauma to the chest 50 years earlier (during bar practice). Cardiac computed tomography revealed a cystic mass wrapped in a calcified membrane that was impeding inflow to the right atrium and ventricle. Cardiac catheterization revealed that the right ventricular pressure had a dip and plateau pattern. We diagnosed the patient with constrictive pericarditis-induced chronic expanding intrapericardial hematoma and agreed upon surgical management. We removed the hematoma and performed a pericardiectomy. The postoperative course was uneventful. In conclusion, chronic expanding intrapericardial hematoma can develop after blunt chest trauma and can be diagnosed precisely with cardiac computed tomography.

Learning objective: A 76-year-old man presented with congestive heart failure. The patient had experienced blunt trauma to the chest 50 years earlier. Cardiac computed tomography (CT) revealed a cystic mass within a calcified membrane that was impeding inflow in the right atrium and ventricle. We diagnosed chronic expanding intrapericardial hematoma (CEIH). We successfully removed the hematoma and performed a pericardiectomy. CEIH can develop after blunt chest trauma and could be diagnosed earlier with cardiac CT.

© 2022 Japanese College of Cardiology. Published by Elsevier Ltd. All rights reserved.

Introduction

A chronic expanding intrapericardial hematoma (CEIH) is a rare epicardial injury that occurs after open-heart surgery [1,2]. As CEIH grows, it can cause impeding inflow to the heart, causing a condition clinically similar to constrictive pericarditis. Furthermore, as the hematoma grows gradually, detection is likely to be delayed.

We report a case who was diagnosed with CEIH using cardiac computed tomography (CT). The patient was subsequently found to have an old, large hematoma that was thought to be caused by blunt trauma to the chest 50 years earlier.

Case report

Written informed consent was obtained from the patient for the publication of this case report. The patient was a 76-year-old man who was referred to us with a diagnosis of congestive heart failure and pitting edema in the lower extremities. The patient's medical history revealed that he had slipped and hit his chest on the ground face-down while performing a giant swing on iron bars. The patient did not visit any hospital, although he was in severe pain. Therefore, no diagnosis of fracture or injury was made at that time. The patient had a blood pressure of 116/80 mmHg and a heart rate of 65 beats/min on admission. Auscultation of the chest did not reveal any abnormal sounds or arrhythmia. Laboratory tests revealed mild liver dysfunction (total bilirubin, 1.5 mg/dL; gamma-glutamyl transferase, 253 U/L) and a brain natriuretic peptide level of 138 pg/mL. The chest X-rays performed at the hospital to which he was referred indicated calcification on several occasions; however, no further examination was specifically performed.

Electrocardiography showed a normal sinus rhythm with inverted T waves in leads II, III, and aVF. Chest radiography showed mild cardiac enlargement with a cardiothoracic ratio of 0.55 as well as calcification in the posterior and lateral portions of the cardiac silhouette. Echocardiography revealed extensive failure of the right atrium (RA) and right ventricle (RV), a dilated inferior vena cava, and an echo-free space that included a mass ventral to the RA and RV (Fig. 1a). Cardiac CT revealed that the mass was a cystic lesion wrapped in a calcified

* Corresponding author at: Department of Cardiovascular Surgery, Chiba-nishi General Hospital, 107-1 Kanegasaku, Matsudo, Chiba 270-2251, Japan.
E-mail address: ystgnkmr@gmail.com (Y. Nakamura).

https://doi.org/10.1016/j.jccase.2022.08.004
1878-5409/© 2022 Japanese College of Cardiology. Published by Elsevier Ltd. All rights reserved.

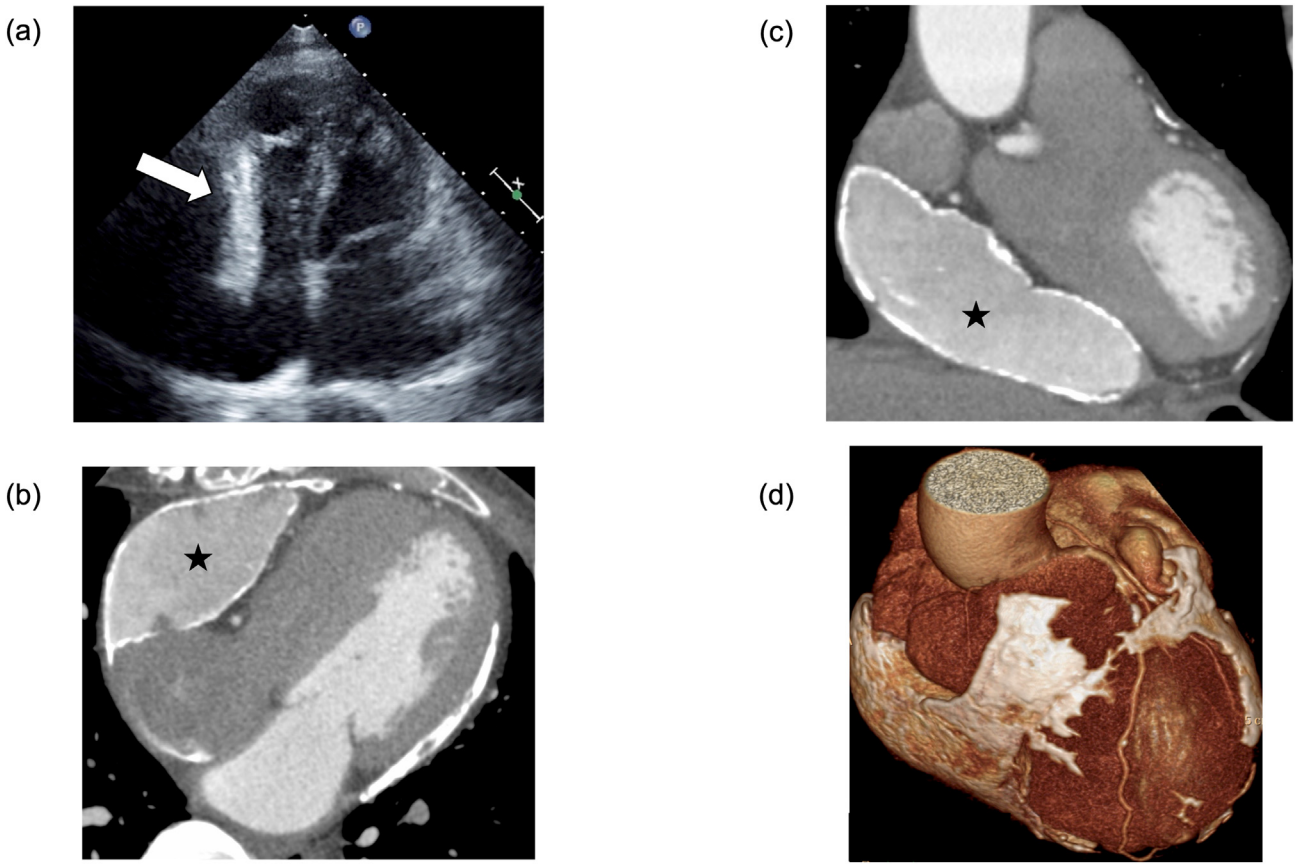

Fig. 1. Echocardiographic findings before surgery and a preoperative cardiac computed tomography (CT) scan showing the cystic lesion (indicated by the star) compressing the heart. (a) A preoperative echocardiogram showing compression of the right ventricle and a cystic lesion (indicated by the white arrow). (b) The axial, (c) coronal, and (d) three-dimensional CT images.

membrane, which was impeding inflow in the RA and RV (Fig. 1b, c, d). The CT scan also showed a heavily calcified mass over the epicardium. Cardiac catheterization revealed elevated end-diastolic pressures in the RA as well as right and left ventricles (26, 26, and, 32 mmHg, respectively). The pressure was 29/26 mmHg in the RA, 56/26 mmHg in the RV with a dip and plateau pattern, 41/22 mmHg in the pulmonary artery, and 148/32 mmHg in the left ventricle, with a mean pulmonary wedge pressure of 26 mmHg. The cardiac index was 2.04 L/min/m^2.

A diagnosis of CEIH and constrictive pericarditis was made, and the patient was scheduled for surgery to remove the old cystic hematoma and heavily calcified pericardium. Under general anesthesia, a median sternotomy was performed, and the pericardium was opened. The cystic mass contained clay-like material covering the RV that was assumed to be old, coagulated blood (Fig. 2). A pathological evaluation of the mass showed results consistent with an organized acellular hematoma. The adherent pericardium was then dissected from the surface of the RA, superior vena cava, and RV. Cardiopulmonary bypass was started, and the calcified lesions on the posterior and lateral surfaces of the pericardium were excised as far as possible. A pathological examination identified iron components on Masson's trichrome staining, precipitation of platelets, and progressive fibrosis, which indicated an old hematoma; these findings were considered consistent with his history of blunt trauma to the chest many years earlier. The removed pericardium showed inflammatory changes on pathological examination.

The postoperative course was uneventful. Echocardiographic findings after surgery showed improvement in the compression and extensive failure of the RA and RV (Fig. 3a). A cardiac CT scan performed postoperatively confirmed that the cystic mass had been removed and calcification around the heart had reduced (Fig. 3b, c, d). An echocardiographic examination showed that the diameter of the inferior vena cava had decreased from 23 mm to 15 mm. Furthermore, the preoperative and postoperative RV pressure waveforms obtained from Swan—Ganz catheterization are shown in Online Fig. 1. The preoperative RV pressure waveform with a dip-and-plateau pattern improved to a normal RV waveform postoperatively. Six months postoperatively, the patient was doing well, with no further heart failure, a gamma-glutamyl transferase level within the normal range, and reduced leg edema.

Discussion

We presented a rare case of CEIH induced by blunt trauma to the chest 50 years earlier. Reid et al. [3] first described a chronic expanding hematoma as a persistent lesion occurring in any location in the body that increases in size more than one month after the initial hemorrhage. There have been several reports of CEIH after cardiac surgery and pericardiocentesis [1–4], but none have been reported to be associated with blunt trauma 50 years earlier. We have limited information on the cause of CEIH in our patient; however, we found no history of a plausible cause of the CEIH other than the chest trauma experienced 50 years ago. We believe that this is a reasonable cause of the CEIH diagnosis since a previous report has also diagnosed CEIH based on medical history [5–9].

CEIH caused by blunt trauma is possible and one report suggested that the etiology and pathogenesis of chronic expanding hematoma may reflect that of chronic subdural hematoma; however, this remains unconfirmed [3]. We searched the electronic databases PubMed and Google Scholar for relevant studies. Search terms included “chronic expanding intrapericardial hematoma,” “blunt chest trauma,” “chest

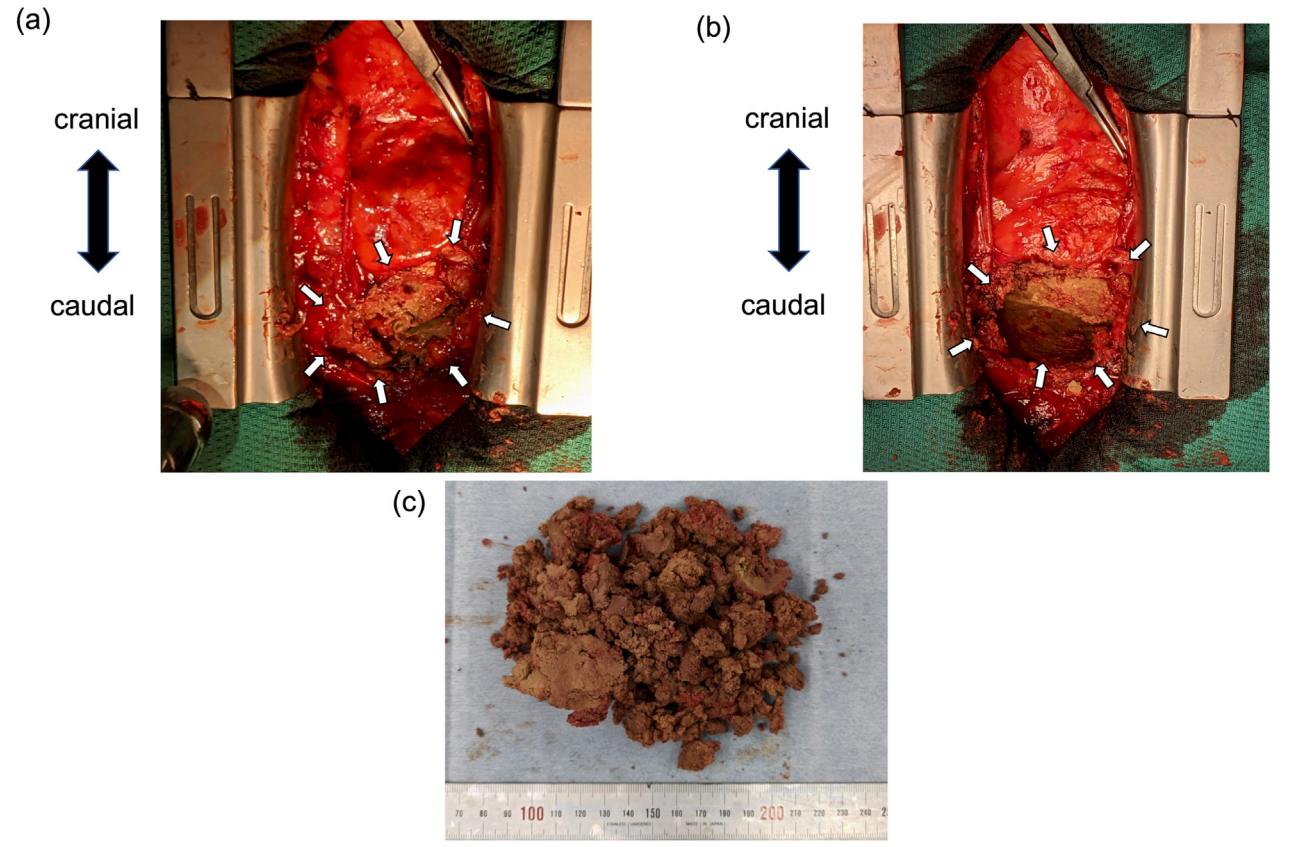

Fig. 2. Clinical photographs obtained at the time of surgery. (a) The contents of the cystic lesion are indicated by the white arrows. (b) The cystic lesion after removal of its contents. (c) The contents of the cystic lesion.

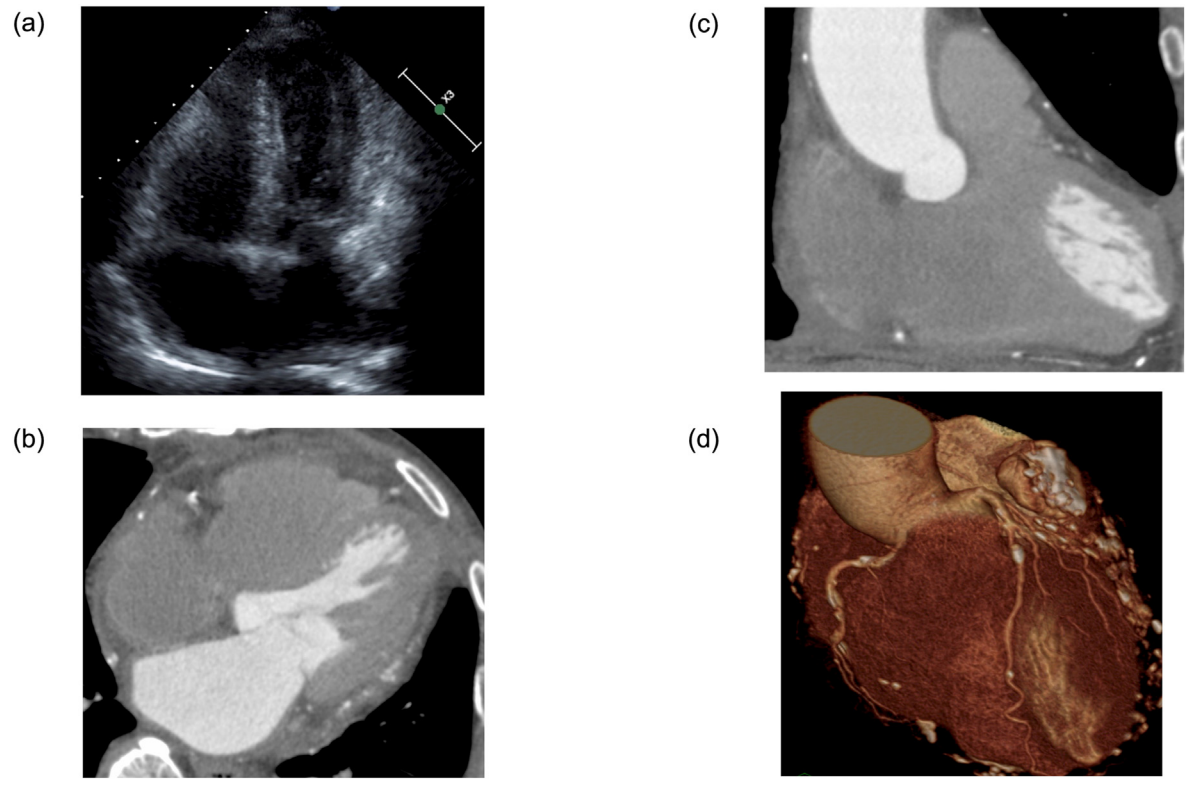

Fig. 3. Echocardiographic findings after surgery and postoperative cardiac computed tomography (CT) scans showing improvement in the compression and extensive failure of the right atrium and ventricle. (a) A postoperative echocardiogram. (b) The axial, (c) coronal, and (d) three-dimensional CT images.

trauma," and "intrapericardial hematoma." Reference lists of appropriate studies were also examined for relevant literature. To the best of our knowledge, only five cases of blunt chest trauma have been reported in the literature [5–9] (Online Table 1) since 1990 to date. To summarize those reports, the mean time interval from the blunt chest trauma to surgery was 2.6 years. In contrast, our patient was treated 50 years after the blunt chest, which is a longer duration compared to previous reports.

At the time of the trauma, the hemorrhage spread slowly, causing inflammation, granulomas, and calcified membranes. This diagnosis is considered very rare.

In this case, a cardiac CT scan revealed a structure that was found to be an old hematoma obscuring the RA and RV. Cardiac CT is an important examination tool that aids our understanding of anatomical structures. The intraoperative findings in this case suggested an old hematoma containing clay-like material, which was consistent with the results of the pathological examination. These results suggest that cardiac CT is a useful and reliable tool for diagnostic purposes. It should be emphasized that CT is superior to echocardiography in terms of capturing the complete image of the CEIH, diagnosing hematomas, and considering surgical procedures by constructing 3D images.

In conclusion, a CEIH can develop after blunt chest trauma. Surgical removal of the old hematoma and a pericardiectomy resulted in a favorable outcome of this patient. A preoperative CT scan was useful for observing the CEIH, highlighting cardiac CT as a useful tool to precisely facilitate diagnosis.

Supplementary data to this article can be found online at https://doi.org/10.1016/j.jccase.2022.08.004.

Declaration of competing interest

The authors declare that there is no conflict of interest.

Acknowledgments

None.

References

[1] Sughiura T, Nishida H, Ishitoya H, Tomizawa Y, Saito S, Endo M, Kurosawa H. Chronic expanding intrapericardial hematoma after pericardial paracentesis. J Card Surg 2006; 21:491–3. https://doi.org/10.1111/j.1540-8191.2006.00307.x.
[2] Kainuma S, Masai T, Yamauchi T, Takeda K, Iwakura K, Ito H, Abe K, Sawa Y. Chronic expanding intrapericardial hematoma after coronary artery bypass surgery presenting with congestive heart failure. Ann Thorac Cardiovasc Surg 2008;14:52–4.
[3] Reid JD, Kommareddi S, Lankerani M, Park MC. Chronic expanding hematomas. A clinicopathologic entity. JAMA 1980;244:2441–2.
[4] Hirai S, Hamanaka Y, Mitsui N, Isaka M, Kobayashi T. Chronic expanding hematoma in the pericardial cavity after cardiac surgery. Ann Thorac Surg 2003;75:1629–31. https://doi.org/10.1016/s0003-4975(02)04779-3.
[5] Ito H, Okamoto R, Inagaki M, Seko T, Kasai A, Tokui T, Ito M, Dohi K. U-shaped intrapericardial chronic expanding hematoma due to blunt chest trauma. Circ Cardiovasc Imaging 2021;14:e011176. https://doi.org/10.1161/CIRCIMAGING.120.011176.
[6] Chamsi-Pasha MA, Anwar AM, Nosir YF, Ajam A. Organized intrapericardial haematoma: a rare cause of heart failure after 2 years of trauma. Eur J Echocardiogr 2011;12:E1. https://doi.org/10.1093/ejechocard/jeq094.
[7] Brown DL, Ivey TD. Giant organized pericardial hematoma producting constrictive pericarditis: case report and review of literature. J Trauma 1996;41:558–60.
[8] Meleca MJ, Hoit BD. Previously unrecognized intrapericardial hematoma leading to refractory abdominal ascites. Chest 1995;108:1747–8.
[9] Hartl WH, Kreuzer E, Reuschel-Janetschek E, Schmidt D, Reichart B. Pericardial mass mimicking constrictive pericarditis. Ann Thorac Surg 1991;52:557–9.