Circulation Journal
Circ J 2022; 86: 1733–1739
doi:10.1253/circj.CJ-22-0282

ORIGINAL ARTICLE
Surgery

Sutureless Aortic Valve Replacement Through Lateral Mini-Thoracotomy

— Feasibility and Effectiveness —

Yoshitsugu Nakamura, MD, PhD; Takuya Narita, MD, PhD; Miho Kuroda, MD; Taisuke Nakayama, MD, PhD; Ryo Tsuruta, MD, PhD; Daiki Yoshiyama, MD; Yuto Yasumoto, MD; Shintaro Sawa, MD; Akira Furutachi, MD, PhD; Yujiro Ito, MD

Background: Minimally invasive sutureless aortic valve replacement with the Perceval bioprosthetic heart valve (MISUAVR) is commonly performed through a right anterior thoracotomy (AT). However, a lateral thoracotomy (LT) may be superior as it does not require rib and right internal thoracic artery (RITA) cutting.

Methods and Results: In total, 38 MISUAVRs performed from May 2019 to approximately August 2021 were retrospectively reviewed; 21 through LT (Group L), and 17 through AT (Group A). In Group L, the skin incision was made on the right anterior axillary line and third intercostal space, and in group A, on the right anterior chest and second or third intercostal space. All other surgical techniques were the same. Age, body surface area, EuroSCORE Ⅱ, and ejection fraction were similar between the patients. Cardiopulmonary bypass (L: 82±19 vs. A: 93±28 min, P=0.19) and cross-clamp times (L: 57±13, vs. A: 64±23 min, P=0.19) were similar. Rib and/or RITA cutting were required in 94.6% of patients in group A and in none of group L (P<0.001). Surgical visualization score was better in group L (L: 1.19±0.40 vs. A: 1.94±0.69, P<0.01). Total amount of intraoperative bleeding was lower in group L (L: 623±141 vs. A: 838±316 mL, P<0.01). Duration of hospital stay was similar (P=0.30).

Conclusions: MISUAVR through LT has multiple advantages over AT.

Key Words: Aortic stenosis; Aortic valve replacement; Minimally invasive; Perceval; Sutureless valve

Sutureless aortic valve replacement (AVR) with the CORCYM Perceval bioprosthetic heart valve (Corcym Canada Corp, Vancouver, Canada) has produced excellent short- and mid-term results with respect to hemodynamic performance and reduction in implantation time.[1–5] These reports have led to acceptance of sutureless AVR as an alternative to conventional aortic valve replacement with stented bioprostheses requiring sutures. The most advantageous feature of sutureless AVR is shorter cross-clamping time compared to conventional AVR.[4,6] Another factor that affects cross-clamping time is surgical approach. A minimally invasive approach for AVR generally requires longer cross-clamping time, even though it is associated with a lower complication rate and early postoperative recovery.[7–9] Thus, combining sutureless AVR with a minimally invasive approach could theoretically offset the disadvantage of longer cross-clamp times.[10]

Minimally invasive sutureless aortic valve replacement (MISUAVR) with the Perceval valve is commonly performed through a right anterior mini-thoracotomy (AT),[10,11] whereas a lateral mini-thoracotomy (LT) is commonly used for minimally invasive mitral valve surgery.[12,13] LT has several advantages compared to AT,[14,15] the latter of which frequently requires cutting of a rib and/or the right internal thoracic artery (RITA), and leaves a greater scar on the anterior chest. We speculated if LT could be applied to aortic valve surgery as well. The aim of this study was to evaluate feasibility and effectiveness of employing a LT in MISUAVR as compared with an AT.

Methods

Patients

This study was approved by the institutional review board of Chibanishi General Hospital. This was a retrospective study of data collected from 37 consecutive MISUAVR patients performed from May 2019 to August 2021. Patients provided written preoperative consent for use of surgical data in research.

Patients who had severe atherosclerotic disease in the

Received May 11, 2022; revised manuscript received June 15, 2022; accepted June 26, 2022; J-STAGE Advance Publication released online July 27, 2022 Time for primary review: 18 days
Department of Cardiovascular Surgery, Chibanishi General Hospital, Matsudo, Japan
Mailing address: Yoshitsugu Nakamura, MD, Department of Cardiovascular Surgery, Chibanishi General Hospital, 107-1 Kanegasaku, Matsudo 270-2251, Japan. E-mail: ystgnkmr@gmail.com
All rights are reserved to the Japanese Circulation Society. For permissions, please e-mail: cj@j-circ.or.jp
ISSN-1346-9843

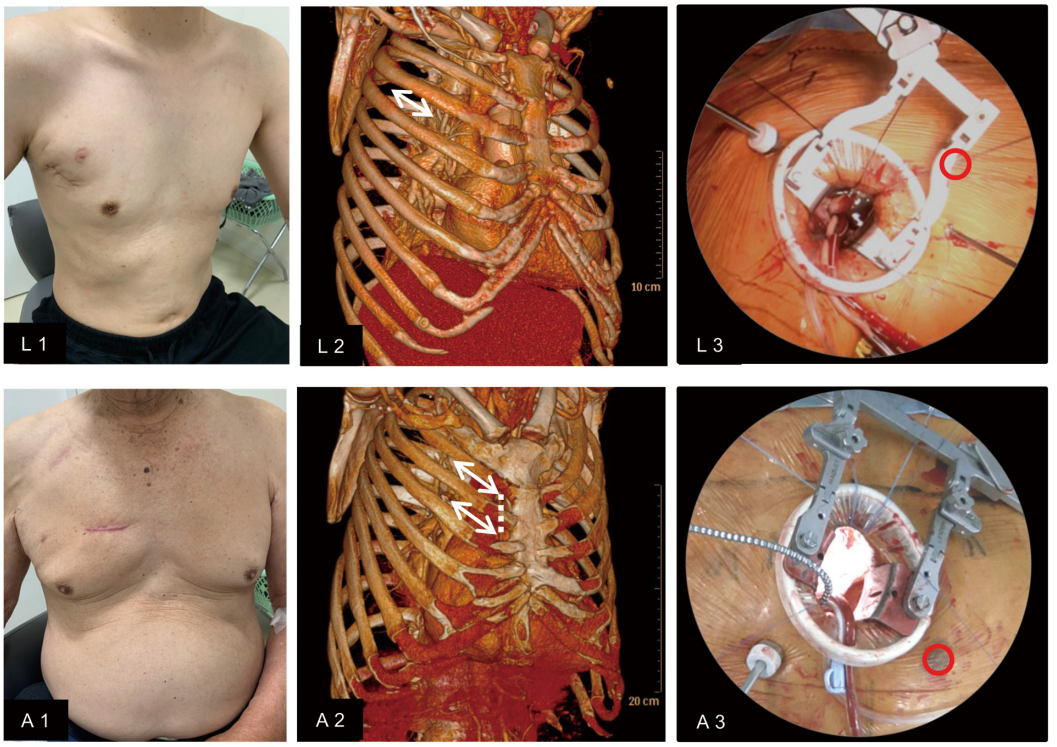

Figure 1. Comparison between lateral thoracotomy (LT) and anterior thoracotomy (AT). **Panel L1**, example of skin incision in LT; **A1**, skin incision in AT. **Panel L2**, white arrows indicates location of thoracotomy in LT; **A2**, white arrows indicate locations of thoracotomy in AT. Either the 2nd or 3rd intercostal space is used depending on patient anatomy. The white dotted line indicates where the rib is cut. **Panel L3**, intraoperative view of thoracotomy in LT; **A3**, intraoperative view of thoracotomy in AT. Red circles indicate the location of the nipple.

ascending aorta, poor cardiac function (left ventricular ejection fraction <30%), severe renal dysfunction (estimated glomerular filtration rate <30 mL/min/1.73 m^2), history of right thoracotomy, or poor lung function (forced expiratory volume during the first second of <1 L) were excluded as candidates for MISUAVR. Another category for MISUAVR exclusions was surgery in which surgeons-in-training were involved. The patients received sutureless AVR through median sternotomy instead, and numbered 30 during the same period as the study.

After performing 17 MISUAVR through AT (patient Group A), we switched to MISUAVR through LT (patient Group L) in August 2020. We compared baseline demographic data, operative data, intensive care unit (ICU) length of stay, hospital length of stay, and adverse outcomes between Groups A and L. We also assessed the surgical visualization score. The surgical visualization score used a 3-point Likert scale in which a score of 1 indicated excellent visualization of total aortic annulus, 2 indicated good visualization of total annulus, and 3 indicated poor visualization of any part of the aortic annulus. The score was determined by the primary surgeon based on the visualization of the aortic valve annulus at the moment of deployment.

Statistical Analysis

Continuous data are presented as mean±standard deviation and were analyzed using a Student's t-test for independent samples. Categorical variables are given as frequencies and percentages and were compared using Chi-squared or Fisher's exact test as appropriate. Two-sided P values were used and $P<0.05$ was considered statistically significant. All data were analyzed using SPSS version 25.0 (IBM Corp., Armonk, NY, USA).

Surgical Procedure

After general anesthesia with differential lung ventilation, patients were placed in a 45° left lateral position with a pillow under the right thorax for LT. A 5-cm skin incision was made on the lateral edge of the pectoralis major muscle in males, and in the lateral mammary crease in females. After dissecting the space under the pectoralis major muscle anteriorly, a thoracotomy incision was made through the third intercostal space. For AT, patients were placed in supine position. A 6-cm skin incision was made at the anterior chest 1 cm lateral to the right edge of the sternum in the second or third intercostal space. The third rib and the RITA were cut if necessary to obtain the minimum necessary visualization for Perceval deployment (**Figure 1**). After the thoracotomy, procedures used were the same in both groups. Cardiopulmonary bypass (CPB) was established via either femoral or axillary arterial cannulation and femoral venous drainage cannulation. Femoral venous cannula positioning was performed under transesophageal echocardiography guidance. Vacuum assistance was used for venous drainage. Perfusion was controlled between 2.2 and 2.6 L/m^2. The lowest blood temperature during CPB

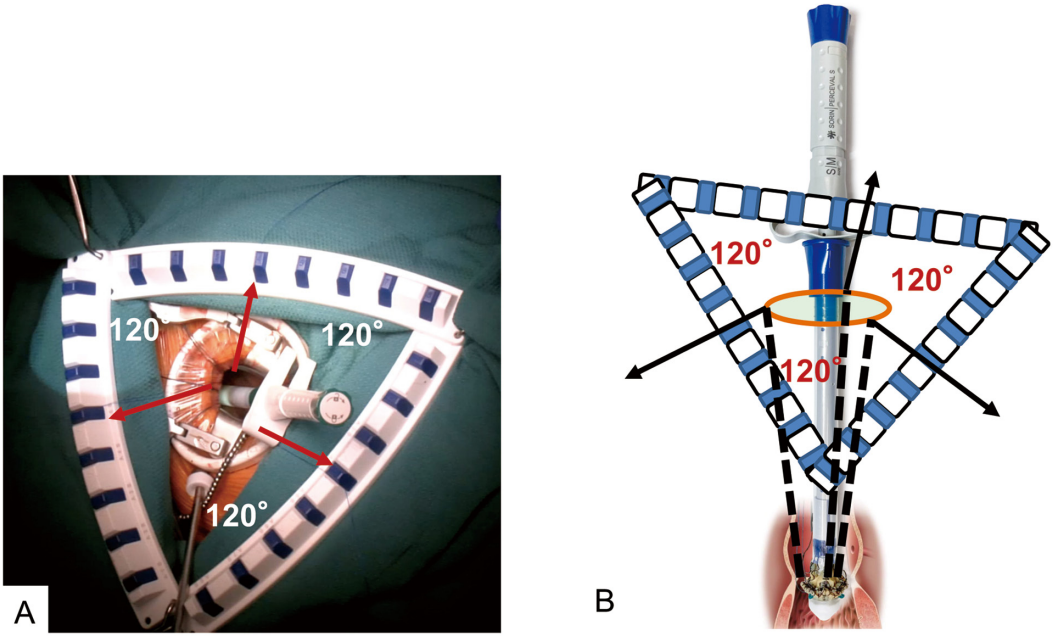

Figure 2. (**A**) Intraoperative view. The red arrows indicate where the 3 guiding sutures will be placed relative to the triangular suture holder. The sutures are placed at roughly 120 degree angles from each other. (**B**) A schematic diagram of the relative positions of the suture holder vs. the prosthetic valve. The orange circle indicates the plane of the skin. The triangular suture holder sits on the chest. The solid black arrows indicate the direction of the guiding sutures corresponding to the red arrows in (**A**). The hashed black arrows indicate the guiding sutures inside the right thoracic cavity. The guiding sutures clamped by the suture holder replace the pulling of guiding sutures by the surgeon and assistant.

Table 1. Patient Characteristics

Characteristics	Group L (N=21)	Group A (N=17)	P value
Age (years)	77.1±5.6	77.1±4.6	0.99
Male	9 (42.9)	5 (29.4)	0.39
BSA (m^2)	1.46±0.17	1.52±0.13	0.18
EuroSCORE (%)	2.2±1.6	2.6±2.3	0.52
NYHA (class III or IV)	2 (9.5)	3 (17.6)	0.46
Atrial fibrillation	2 (9.5)	2 (11.8)	0.82
Complete RBBB	0 (0)	2 (11.8)	0.11
Complete LBBB	0 (0)	1 (5.9)	0.26
Pulmonary hypertension	2 (9.5)	2 (11.8)	0.82
Cerebrovascular disease history	4 (19.0)	2 (11.8)	0.54
Diabetes mellitus	8 (38.1)	3 (17.6)	0.17
COPD	2 (9.5)	2 (11.8)	0.82
Chronic kidney disease	6 (28.6)	3 (17.6)	0.43
Hemodialysis	4 (19.0)	2 (11.8)	0.54
Peripheral artery disease	2 (9.5)	1 (5.9)	0.67
Redo case	0 (0)	0 (0)	–
Bicuspid aortic valve	3 (14.3)	2 (11.8)	0.82
LVEF (%)	65.1±12.3	64.2±10.8	0.82

Data for continuous variables are presented as mean±standard deviation and data for categorical variables are presented as n (%). BSA, body surface area; COPD, chronic obstructive pulmonary disease; EuroSCORE, European System for Cardiac Operative Risk Evaluation; LBBB, left bundle branch block; LVEF, left ventricular ejection fraction; NYHA, New York Heart Association; RBBB, right bundle branch block.

Table 2. Intraoperative Data

Variable	Group L (N=21)	Group A (N=17)	P value
Vale size			
S	14 (66.7)	9 (52.9)	0.55
M	6 (28.6)	5 (29.4)	
L	1 (4.8)	2 (11.8)	
XL	0 (0)	1 (5.9)	
Concomitant procedure	2 (9.5)	0	0.90
Conversion to sternotomy	0 (0)	0 (0)	–
First attempt success	21 (100)	16 (94.1)	0.26
Final successful cases	21 (100)	17 (100)	–
Rib cutting / Sacrifice of RITA	0 (0)	16 (94.1)	<0.01
- Rib cutting	0 (0)	9 (52.9)	<0.01
- Sacrifice of RITA	0 (0)	16 (94.1)	<0.01
Blood loss (including cell-saver blood), mL	623±141	838±316	0.02
Blood transfusion	6 (28.6)	5 (29.4)	0.30
Surgical visualization score	1.19±0.40	1.94±0.69	<0.01
Procedure time (min)	157±46	181±42	0.12
CPB time (min)	82±19	93±28	0.19
Cross-clamp time (min)	57±17	64±23	0.30

Data for continuous variables are presented as mean±standard deviation and data for categorical variables are presented as n (%). CPB, cardiopulmonary bypass; RITA, right internal thoracic artery.

was 32°C. CO_2 insufflation into the right thoracic cavity was performed with a flow of 5 L/min. After insertion of the aortic root cannula, the ascending aorta was cross-clamped using a Cygnet flexible clamp (Vitalitec Inc., MA, USA) through the main incision. All procedures were performed under direct vision with thoracoscopic assistance. After cross-clamping the ascending aorta, antegrade cardioplegia was delivered through a root cannula into the aortic root. An aortotomy was made 2.5 cm above the orifice of the right coronary sinus. In both groups, procedures for MISUAVR with Perceval were the same in terms of sizing, pacing guiding sutures, and deployment of Perceval. A Dual MICS holder (Corcym Canada Corp) was used for all cases in both groups. The only differences were as follows: in Group L, all 3 guiding sutures were fixed by Suture Guides (Surg Cardiovascular, MI, USA) (**Figure 2**), whereas in Group A, all 3 sutures were pulled and held manually by the surgeon and assistant. All patients were transferred to the intensive care unit where they were extubated. The chest drains were removed when the discharge decreased to <50 mL/12 h.

Results

Patient Characteristics

Baseline patient characteristics are summarized in **Table 1**. Thirty-eight consecutive patients receiving MISAVR were included in this study (Group L: 21 patients, Group A: 17 patients). The pathology of the aortic valve was severe aortic stenosis in all cases. Two patients in Group L and 3 patients in Group A had significant aortic regurgitation (greater than mild) associated with aortic stenosis. There were no significant differences in age, gender, body mass index, and European System for Cardiac Operative Risk Evaluation (EuroSCORE) II. The incidences of comorbidities including atrial fibrillation, bundle branch block, history of cerebrovascular disease, diabetes, chronic obstructive pulmonary disease, chronic kidney disease, hemodialysis, and peripheral arterial disease did not differ between the groups. Preoperative echocardiography showed no significant differences in left ventricular ejection fraction and prevalence of bicuspid valve between the 2 groups. In terms of anatomical features, there was no significant difference between the groups regarding angle of the ascending aorta from the horizontal level (Group L: 49.0±8.4 vs. Group A: 49.1±7.0 degrees, P=0.99), distance from the sternum to the anterior wall of the ascending aorta (Group L: 19.0±8.1 vs. Group A: 15.1±9.8 mm, P=0.32), and lateral deviation of the ascending aorta (distance from the right edge of the sternum to the center of the ascending aorta) (Group L: −0.9±9.5 vs. Group A: −3.4±6.7 mm, P=0.15).

Intraoperative Data

Intraoperative data are summarized in **Table 2**. Size distributions of the implanted Perceval valves were not different (P=0.55). There were 2 concomitant procedures in Group L (left atrial cryoablation in one and mitral valve repair in the other). There was no conversion to sternotomy in either group. There was 1 patient in group A who required a second deployment of a Perceval valve intraoperatively because of a moderate paravalvular leak after declamping. In this particular case, the ascending aorta was re-clamped. Then, the first Perceval valve (size S) was removed, and a new Perceval valve (size M) was deployed. No paravalvular leak was observed after the second declamping. The final success rate of Perceval valve implantation including the patient requiring the second attempt was 100% in both groups. No patient required rib cutting or sacrifice of the RITA in Group L. In Group A, 16 patients (94.1%) required a sacrifice of the RITA (P<0.01), 9 of whom also required rib cutting. Total amount of intraoperative bleeding including cell-saver blood was significantly less in Group L than in Group A (Group L 623±141 vs. Group A 838±316 mL, P=0.02). However, the blood transfusion rate

Table 3. Postoperative Data

Variable	Group L (N=21)	Group A (N=17)	P value
Hospital mortality	0 (0)	0 (0)	–
Re-exploration	0 (0)	0 (0)	–
Neurological events	0 (0)	0 (0)	–
Acute kidney injury	0 (0)	0 (0)	–
Complete AV block	0 (0)	0 (0)	–
Hospital stay (days)	10.3±3.1	11.6±4.2	0.30
ICU stay (days)	2.2±1.0	2.4±1.1	0.74
Duration of ventilation (h)	7.4±3.7	7.6±4.9	0.88
Total drain output (mL)	472.4±398.8	422.4±351.4	0.68
Timing of drain removal (postoperative days)	1.4±0.8	1.5±0.7	0.72

Data for continuous variables are presented as mean±standard deviation and data for categorical variables are presented as n (%). AV, atrioventricular; ICU, intensive care unit.

Table 4. Postoperative Echocardiographic Data

Variable	Group L (N=21)	Group A (N=17)	P value
LVEF	60.6±12.1	56.8±12.9	0.35
Maximum PG (mmHg)	26.7±7.8	22.7±6.0	0.09
Peak aortic jet velocity (m/s)	2.6±0.4	2.4±0.3	0.05
Mean PG (mmHg)	14.8±4.6	12.3±3.6	0.06
Paravalvular Leak, n (%)	0 (0)	0 (0)	–

Data for continuous variables are presented as mean±standard deviation and data for categorical variables are presented as n (%). LVEF, left ventricular ejection fraction; PG, pressure gradient.

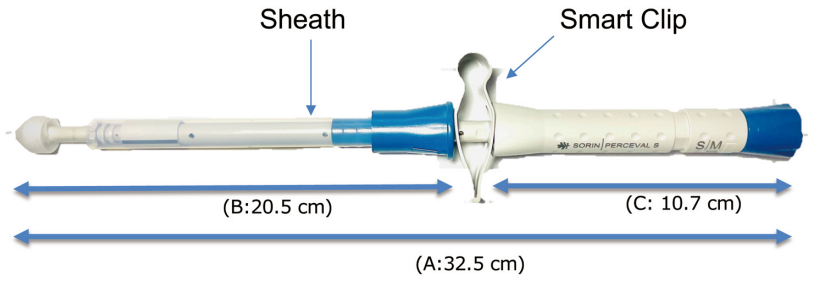

Figure 3. Schematic diagram of Dual MICS holder. The lengths of the various parts of the Dual MICS holder in this figure are actual measurements made by the authors and are not available in the manufacturer's product specifications.

was not significantly different. The surgical visualization score was better in Group L than in Group A (Group L 1.19±0.40 vs. 1.94±0.69 Group A, P<0.01). Procedure time, CPB time, and cross-clamp time were not significantly different between the 2 groups.

Postoperative Data

Postoperative data are summarized in **Table 3**. There was no in-hospital mortality in either group. Group L had 1 case of respiratory failure (4.8%). There was no re-exploration, cerebral infarction, acute kidney injury or complete atrioventricular block in either group. There was no significant difference in length of hospital stay, intensive care unit stay, duration of ventilation and total drain output between the 2 groups. Postoperative echocardiographic data (**Table 4**) before discharge showed that the mean pressure gradient did not differ statistically (Group L: 14.8±4.6 vs. Group A: 12.3±3.6, P=0.06). There was no paravalvular leak in either group.

Discussion

The present study revealed that the safety and effectiveness of MISUAVR through LT is comparable to AT. Postoperative echocardiographic data showed excellent hemodynamic performance of the implanted Perceval valve in both groups. They were comparable to surgical results reported in previous studies. Intraoperative data showed MISUAVR through LT was not time-consuming. MISUAVR is commonly performed through an AT,[10,11] and this is the first report of MISUAVR through LT to our knowledge. Initially, we believed that the limitations of the Perceval holder length made any minimally invasive approach other than AT impossible and so we started with AT. However,

as we gained experience, we found there were cases in which small incisions and valvular coaxiality were difficult to achieve, leading to poor surgical visualization. Based on our familiarity with minimally invasive AVR using stented valves and LT, we knew that LT provided good surgical visualization even if the distance from the skin incision was long. So we hypothesized that LT could be beneficial for Perceval placement, which requires coaxiality. With respect to the problem of distance, because the length of the sheath of the dual MICS holder is 20.5 cm (**Figure 3**), we used a dry laboratory to confirm cases, in which the distance between expected skin incision site and the aortic valve was less than approximately 20 cm, before transitioning to the use of LT in real patients.

LT has several advantages compared to AT in terms of invasiveness. In this study, there was no RITA sacrifice or rib cutting in Group L, whereas they were required in roughly 90% and 50% of patients respectively in Group A. Amount of bleeding was significantly less in Group L. We speculate that preservation of RITA and ribs contributed to this difference. Thus, we believe LT should always be considered as one of the approaches for MISUAVR. We also believe that for any surgeon who performs minimally invasive AVR with LT and sutureless AVR via median sternotomy competently, performing MISUAVR with LT should be straightforward, even with no prior experience with AT.

A technical advantage of MISUAVR through LT is that the combination of the small skin incision and suture-holder play the role of assisting hands pulling on the guiding sutures. In median sternotomy and AT cases, all 3 guiding sutures must be pulled firmly and optimally during deployment. They need to be pulled at a narrow angle to the holder and held immobile to prevent tilting of the valve at deployment. Normally, the primary surgeon pulls 1 of the 3 sutures and a first assistant pulls the other 2 sutures. This manual technique occasionally can be unsteady because the assistant who pulls the sutures cannot see the aortic annulus, especially in the minimally invasive approach. In MISUAVR through LT, all 3 guiding sutures can be fixed by the suture-holder and completely mimic the manual pulling of the guiding sutures at a narrow angle close to the Perceval Dual MICS holder by a surgeon and an assistant (**Figure 2**). Through experience, we came to realize this technique was much easier than manual fixation and extremely useful for stable deployment.

A disadvantage of LT is the further distance from skin incision to the aortic valve. This is why LT has not been popular for AVR. Ito et al reported that LT is not as remote from the ascending aorta as one might imagine, because the rib cage is narrower cranially.[14] Nevertheless, resection of the calcified aortic valve may be more difficult in LT because the distance is longer than that for AT. However, use of long shaft Monroe scissors specially designed for minimally invasive AVR (Midorija, Tokyo, Japan) and a long shaft ultrasonic aspirator should make resection of the calcified aortic valve relatively easy even in that case. Moreover, SUAVR is simple and reproducible as several surgical steps such as placing sutures and tying knots are eliminated. The long-shaft Perceval Dual MICS holder for the minimally invasive approach was long enough to use in all cases in Group L in our study. We believe therefore that remoteness is not an issue in SUAVR through LT compared to minimally invasive AVR with a stented valve. Rather, the improved visualization of the aortic annulus is more important than remoteness. Coaxiality between the axis of the Perceval Dual MICS holder, and the axis from the skin incision to the aortic annulus is crucial for deployment of the Perceval valve. Considering this, LT is a better technique to use. In this study, the surgical visualization score was better with LT, despite the fact that a rib was cut in 50% of the AT patients to obtain surgical exposure of the aortic annulus. We believe this is because in LT, the aortic valve is seen head on, due to the aortic valve facing the right shoulder in most patients.

Study Limitations

There are several limitations to this study. First, it was a non-randomized retrospective observational study. Second, the study population was small. Third, a chronological bias might exist because after performing 17 MISUAVR through AT, we switched to MISUAVR through LT. Finally, the cohort of this study was all Japanese with a body surface area (BSA) approximately 1.5 m^2. The long-shaft Perceval Dual MICS holder was long enough to be used for all cases in Group L; however, patients with a larger build in other countries would have a greater distance between their skin incision and aortic valve. The length between the loaded Perceval valve and the Smart Clip (the clip that holds the sheath to keep the outflow ring of Perceval valve inside it) of the Perceval Dual MICS holder is 20.5 cm (Part B in **Figure 3**). If the distance between the skin incision in LT and aortic valve is longer than 20.5 cm, the Smart Clip of the holder will occupy the area inside the skin incision hindering surgical visualization. In that case, the Smart Clip can be pulled out before applying the valve into the aortic annulus, although that is not the intended way of use. Surgeons should hold the sheath of the holder (**Figure 3**) at its original position, so it is not pulled back accidentally until the outflow ring is released.

Conclusions

MISUAVR through LT is feasible and is superior to AT in terms of the amount of injury to the chest wall.

Sources of Funding

This study received no specific funding.

Disclosures

Y. Nakamura is a local Master Proctor of the Perceval valve in Japan.

Author Contributions

Y. Nakamura: Conceptualization, data curation, formal analysis, visualization, investigation, methodology, project administration, writing the original draft, writing, review and editing. T. Narita: Data curation, investigation. M. Kuroda: Data curation. T. Nakayama: Data curation. R. Tsuruta: Data curation. D. Yoshiyama: Data curation. Y. Yasumoto: Data curation. S. Sawa; Investigation. Y. Ito: Data curation. A. Furutachi: Data curation.

The procedures in this manuscript were performed in accordance with the "Declaration of Helsinki" and ethical standards of the responsible institutional committee on human experimentation.

IRB Information

This study was approved by the Tokushukai Group Ethics Committee Review Board (TGE00727-025).

References

1. Powell R, Pelletier MP, Chu MWA, Bouchard D, Melvin KN,

Adams C. The perceval sutureless aortic valve: Review of outcomes, complications, and future direction. *Innovations* 2017; **12:** 155–173.
2. Lam KY, Reardon MJ, Yakubov SJ, Modine T, Fremes S, Torino PAL, et al. Surgical sutureless and sutured aortic valve replacement in low-risk patients. *Ann Thorac Surg* 2022; **113:** 616–622.
3. Qureshi SH, Boulemden A, Szafranek A, Vhora H. Meta-analysis of sutureless technology versus standard aortic valve replacement and transcatheter aortic valve replacement. *Eur J Cardiothorac Surg* 2017; **53:** 463–471.
4. Di Eusanio M, Phan K, Berretta P, Carrel TP, Andreas M, Santarpino G, et al. Sutureless and rapid-deployment aortic valve replacement international registry (SURD-IR): Early results from 3343 patients. *Eur J Cardiothorac Surg* 2018; **54:** 768–773.
5. Szecel D, Eurlings R, Rega F, Verbrugghe P, Meuris B. Perceval sutureless aortic valve implantation: Midterm outcomes. *Ann Thorac Surg* 2021; **111:** 1331–1337.
6. Ensminger S, Fujita B, Bauer T, Mollmann H, Beckmann A, Bekeredjian R, et al. Rapid deployment versus conventional bioprosthetic valve replacement for aortic stenosis. *J Am Coll Cardiol* 2018; **71:** 1417–1428.
7. Chang C, Raza S, Altarabsheh SE, Delozier S, Sharma UM, Zia A. Minimally invasive approaches to surgical aortic valve replacement: A meta-analysis. *Ann Thoracic Surg* 2018; **106:** 1881–1889.
8. Masuda T, Nakamura Y, Ito Y, Kuroda M, Nishijima S, Okuzono Y, et al. The learning curve of minimally invasive aortic valve replacement for aortic valve replacement. *Gen Thorac Cardiovasc Surg* 2020; **68:** 565–570.
9. Nakayama T, Nakamura Y, Kanamori K, Hirano T, Kuroda M, Nishijima S, et al. Early and midterm results of minimally invasive aortic and mitral valve surgery via right mini-thoracotomy. *J Card Surg* 2020; **35:** 35–39.
10. Solinas M, Bianchi G, Chiaramonti F, Margaryan R, Kallushi E, Gasbarri T, et al. Right anterior mini-thoracotomy and sutureless valves: The perfect marriage. *Ann Cardiothorac Surg* 2020; **9:** 305–313.
11. Glauber M, Di Bacco L, Cuenca J, Di Bartolomeo R, Baghai M, Zakova D, et al. Minimally invasive aortic valve replacement with sutureless valves: Results from an international prospective registry. *Innovations* 2020; **15:** 120–130.
12. Bowdish ME, Elsayed RS, Tatum JM, Cohen RG, Mack WJ, Abt B, et al. Equivalent outcomes with minimally invasive and sternotomy mitral valve repair for degenerative mitral valve disease. *J Card Surg* 2021; **36:** 2636–2643.
13. Nakayama T, Nakamura Y, Yasumoto Y, Yoshiyama D, Kuroda M, Nishijima S, at al. Early and mid-term outcomes of minimally invasive mitral valve repair via mini-thoracotomy: 5-year experience with 129 consecutive patients. *Gen Thorac Cardiovasc Surg* 2021; **69:** 1174–1184.
14. Ito T, Maekawa A, Hoshino S, Hayashi Y. Right infra-axillary mini-thoracotomy for aortic valve replacement. *Ann Cardiothorac Surg* 2015; **73:** 510–515.
15. Yamazaki M, Yoshitake A, Takahashi T, Ito T, Kimura N, Hirano A, et al. Stonehenge technique is associated with faster aortic clamp time in group of minimally invasive aortic valve replacement via right infra-axillary thoracotomy. *Gen Thorac Cardiovasc Surg* 2018; **66:** 700–706.