Journal of Cardiology Cases 27 (2023) 159–161

Contents lists available at ScienceDirect

Journal of Cardiology Cases

journal homepage: www.elsevier.com/locate/jccase

Case Report

An elderly case of aortic stenosis associated with double-chambered right ventricle

Yuto Yasumoto (MD), Yoshitsugu Nakamura (MD, PhD) *, Masaki Ushijima (MD), Daiki Yoshiyama (MD), Miho Kuroda (MD), Shintaro Sawa (MD), Taisuke Nakayama (MD, PhD), Takuya Narita (MD, PhD), Akira Furutachi (MD, PhD), Ryo Tsuruta (MD, PhD), Yujiro Ito (MD)

Department of Cardiovascular Surgery, Chiba-Nishi General Hospital, Matsudo, Chiba prefecture, Japan

ARTICLE INFO

Article history:
Received 24 July 2022
Received in revised form 28 November 2022
Accepted 5 December 2022

Keywords:
Double-chambered right ventricle
Aortic stenosis
Elderly

ABSTRACT

Double-chambered right ventricle (DCRV) caused by right ventricular outflow tract obstruction, is a developmental cardiac anomaly in which the anomalous muscle bundles divide the right ventricular cavity into two chambers. Few cases with DCRV coexisting with severe aortic stenosis (AS) have been reported. Moreover, adult cases are extremely uncommon.

We report an elderly case of a heavy DCRV with severe AS detected by transthoracic echocardiography and catheterization study. An 85-year-old woman with dyspnea on effort and right-sided heart failure was diagnosed with DCRV and severe AS by echocardiography. She underwent a resection of the anomalous muscle of the right ventricle and aortic valve replacement. Her symptoms disappeared postoperatively and was discharged home. At 2 years postoperatively, she was generally well without recurrence of DCRV. In conclusion, the case of DCRV with AS is rare and surgery is useful to relieve the heart failure symptoms and improve the prognosis of both young and adult patients.

Learning objective: Double-chambered right ventricle (DCRV) is uncommon in the older population; however, clinicians should consider DCRV in patients with right-sided heart failure as a differential diagnosis. The case of DCRV with aortic stenosis is rare, surgical treatment is particularly useful for these patients to relieve the heart failure symptoms and improve the prognosis in young and adult cases.

© 2023 Japanese College of Cardiology. Published by Elsevier Ltd. All rights reserved.

Introduction

A case of double-chambered right ventricle (DCRV) was first reported by Peacock in 1867 as a constriction of the proximal portion of the infundibulum.[1] It presents in 0.5 % to 2 % of all patients with congenital heart disease. It causes right-sided heart failure and patients with this condition require a surgical procedure for symptom improvement. DCRV presents atypically in adults with a prevalence of 2.1 % among patients, but the prognosis is good if patients receive appropriate surgical treatment.[2] To our knowledge, there has been no study or case report on an elderly DCRV case accompanied by aortic stenosis (AS). Therefore, we report a case of heavy DCRV with severe AS detected by transthoracic echocardiography and catheterization study.

Case report

An 85-year-old woman complained of dyspnea and the presence of pitting-edema on her legs for a month. She had previously been diagnosed with New York Heart Association class II heart failure. Past medical history revealed that she had diabetes mellites controlled by medication. During the presentation, her chest X-ray showed an expansion of the heart shadow and left pleural effusion. Upon auscultation left-sided parasternal systolic murmur was noted, which had displaced lower along the sternal border, as compared to a typical systolic murmur. On the first transthoracic echocardiography, the ejection fraction was 71 % with a left ventricular end-diastolic diameter of 33.3 mm and end-systolic diameter of 20.1 mm, and AS was detected. The aortic valve area was 0.3 cm^2, and the mean pressure gradient was 52 mmHg. She also had right ventricular (RV) failure, which is inexplicable by AS. Further investigation revealed right ventricular outflow tract (RVOT) stenosis. The abnormal muscle was present from the distal portion of the moderator band to the infundibulum, causing a high-pressure

* Corresponding author at: Department of Cardiovascular Surgery, Chiba-Nishi General Hospital, 107-1 Kanagasaku, Matsudo, Chiba prefecture, Japan.
E-mail address: ystgnkmr@gmail.com (Y. Nakamura).

https://doi.org/10.1016/j.jccase.2022.12.011
1878-5409/© 2023 Japanese College of Cardiology. Published by Elsevier Ltd. All rights reserved.

chamber (mean pressure gradient of 90 mmHg). The low-pressure chamber was observed between the pulmonary valve annulus and the infundibulum. There was no ventricular septal defect (VSD). Computed tomography also showed the high-pressure and low-pressure chamber within the RV, which was consistent with the diagnosis of DCRV (Fig. 1A, B). Swan-Ganz catheterization demonstrated a suprasystemic RV pressure of 178/14 mmHg, as compared to a pulmonary artery pressure of 40/22/26 mmHg and RVOT stenosis (Fig. 2). Based on the above-mentioned examination findings and clinical symptoms, surgical resection of the myocardium of the RVOT and aortic valve replacement (AVR) was required.

The patient underwent a repair of the DCRV and AVR with median sternotomy under general anesthesia. Preoperative computed tomography angiography (CTA) showed that the unusual myocardium was located just under the pulmonary valve (Fig. 1A,B); therefore, a transventricular view was considered the best approach. The abnormal myocardium occupied the internal space of the RVOT (Fig. 3). The extra muscle tissue was completely excised but not extended to pulmonary valve annulus.[3] The ventricular incision was closed with a patch (Hemashield Woven Double Velour Cardiovascular SAS, La Ciotat, France) to prevent RVOT interspace narrowing (Fig. 1C, D). The aortic valve was composed of tricuspid and calcified as arteriosclerosis, not rheumatic. AVR was performed using a sutureless valve, CORCYM Perceval bioprosthetic heart valve size S (Corcym Canada Corp, Vancouver, Canada).

The operative time was 253 min, and the cardiopulmonary bypass time was 126 min. She was kept in the intensive care unit for 4 days after that.

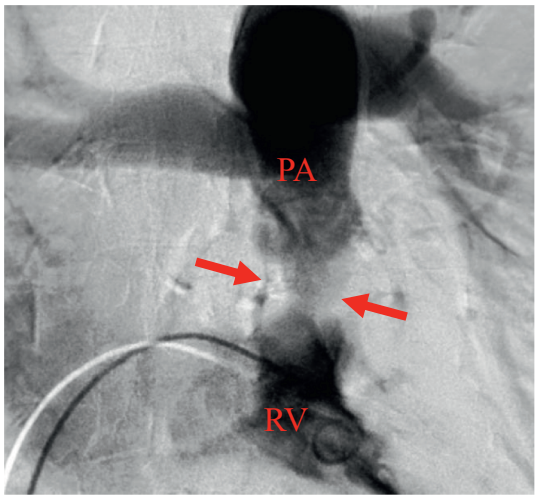

Fig. 2. Right ventricular angiography showed right ventricular outflow tract stenosis.

Postoperative echocardiography showed a diminished pressure gradient around the pulmonary valve and no problem with the prosthetic valve. Swan-Ganz catheterization postoperatively showed a reduction of the RVOT pressure gradient (pulmonary artery pressure of 24/4 mmHg, suprasystemic RV pressure of 42/2 mmHg, and RV pressure of

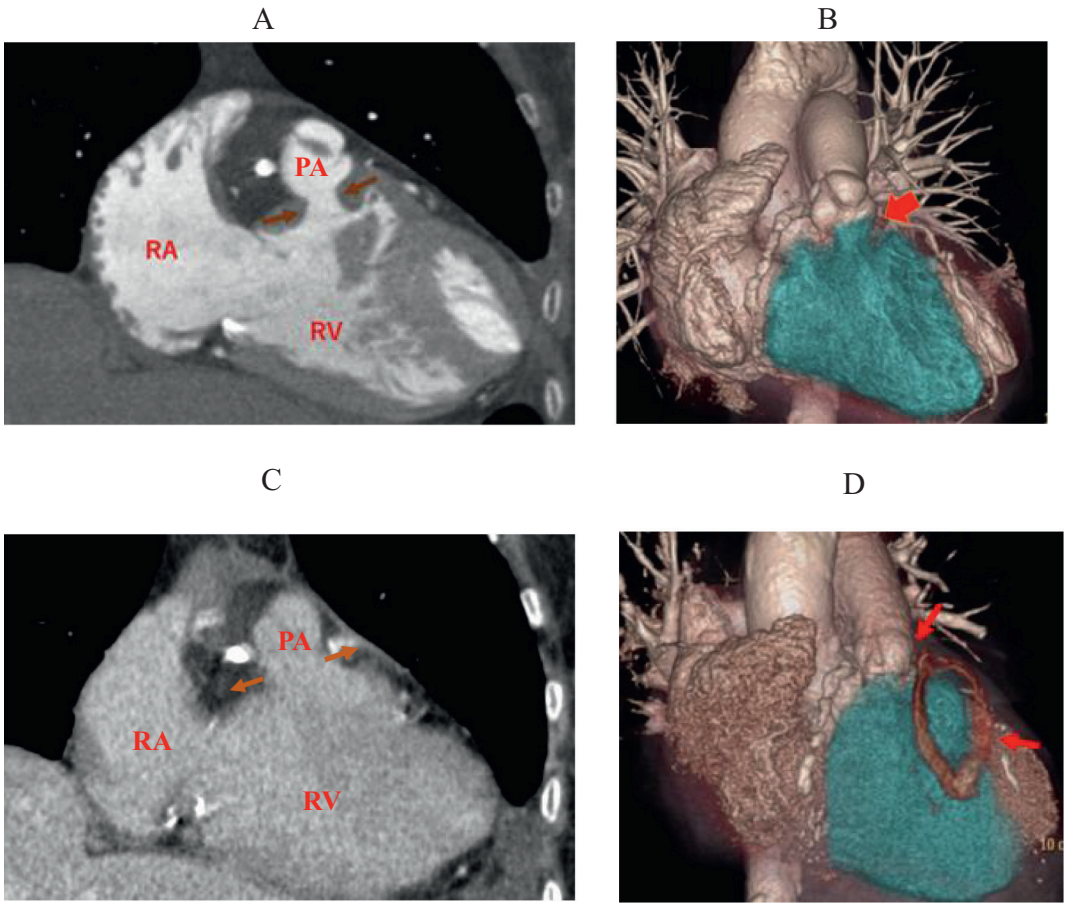

Fig. 1. (A) Preoperative computed tomography shows RVOT stenosis. Red dagger shows abnormal myocardium and stenosis. (B) Preoperative computed tomography shows low- and high-pressure chamber with RVOT stenosis. Red dagger shows abnormal myocardium and stenosis. (C) Postoperative computed tomography shows released RVOT stenosis. Blue star shows resected myocardium and released stenosis. (D) Postoperative coronary computed tomographic reconstruction shows patch repair.
RVOT, right ventricular outflow tract.

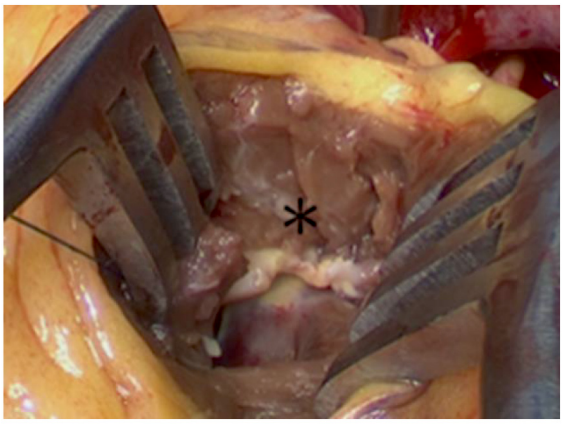

Fig. 3. View of right ventricular incision shows right ventricular outflow tract stenosis caused by abnormal myocardium.
*Shows abnormal myocardium.

16/5 mmHg). CTA after the operation showed a remarkably enlarged RVOT diameter (Fig. 1C, D).

The patient's heart failure symptoms improved after the operation. She was discharged at 30 days postoperatively, with a favorable outpatient outcome 2 years after the operation.

Discussion

There has been no study or case report on elderly DCRV cases with AS in our database search, which was conducted using electronic databases from inception to May 2022 using prespecified key words. The database search was restricted to articles in the English language. Several keyword combinations were tried, but the keyword combination [(DCRV) AND (Adults)] retrieved the most pertinent results. A total of 15 studies were identified through database searches. The maximum age of DCRV patients in these articles is 38 years.

We adventitiously diagnosed DCRV for an elderly patient with severe AS, whose surgical treatment outcomes were satisfactory.

DCRV presents in 0.5 % to 2 % of all patients with congenital heart disease. It can present in 10 % of children undergoing correction of a VSD, and 3.1 % of patients who have undergone repair of tetralogy of Fallot. It can also present atypically in adults with a prevalence of 2.1 %. A patient with DCRV reportedly remains asymptomatic while the obstruction progresses gradually until it presents in adulthood.[1] Almost all adult DCRV cases are symptomatic until the high gradient between the two chambers progresses. DCRV is diagnosed using the following criteria[1]: a pressure gradient across the anomalous bundle within the RV observed by echocardiogram or cardiac catheterization; angiography demonstrating an unusual RVOT obstruction; absence of infundibular hypoplasia; and surgical confirmation of DCRV in the operating room. This case fulfilled these criteria; therefore, we diagnosed the patient as having DCRV.

She had not received treatment for chronic heart failure until then, of course not indicated tetralogy of Fallot. Here, the anomalous bundle of the RVOT muscle grew very slowly, eventually leading to heart failure. She had a systolic murmur caused by both severe AS and DCRV; DCRV sound was masked by severe AS. She had right- and left-sided heart failure.

Surgery is effective for DCRV patients.[2,4] It is generally performed for DCRV patients with an RV pressure gradient of >40 mmHg, or with severe VSD flow (Qp/Qs ≥2.0).[5] The DCRV repair procedure must be able to correct the anomaly by removing the excrescent muscle around the RVOT to control the pressure gradient. Transventricular, transatrial, and combined transatrial-ventricular approaches are used. Right atriotomy and combined transatrial–transpulmonary incisions are the most commonly used approaches because they exclude the bundle.[1,6,7] Right ventriculotomy is usually avoided to reduce ventricular arrhythmias or RV dysfunction.[1,7] The obstruction in this case was severe and too bulky to be excised using the right atriotomy approach; therefore, the transventricular approach was used for the resection of the abnormal shelf of RVOT muscle.[2,8] Moreover, RV was closed with a patch based on the RV size after the completion of the resection procedure. The surgical removal of the obstructing muscle bundle in DCRV patients has a relatively low risk and offers good long-term hemodynamic and functional results.[4,5] However, this report was nothing more than one case, and further studies or case reports of DCRV with AS should be accumulated for the establishment of the treatment.

Declaration of competing interest

The authors declare that there is no conflict of interest.

Acknowledgments

We would like to thank Dr. Fumiaki Shikata for meaningful discussion and advice.

References

[1] Loukas M, Housman B, Blaak C, Kralovic S, Tubbs RS, Anderson RH. Double-chambered right ventricle: a review. Cardiovasc Pathol 2013;22:417–23.
[2] Alva C, Ho SY, Lincoln CR, Rigby ML, Wright A, Anderson RH. The nature of the obstructive muscular bundles in double-chambered right ventricle. J Thorac Cardiovasc Surg 1999;117:1180–8.
[3] Kato T, Takama N, Harada T, Obokata M, Kurosawa K, Kurabayashi M, et al. A case of subvalvular pulmonary stenosis differentiated from a double-chambered right ventricle by transesophageal echocardiography: importance of detecting the pulmonary valve. J Med Ultrason 2001;2020(47):643–4.
[4] Said SM, Burkhart HM, Dearani JA, O'Leary PW, Ammash NM, Schaff HV. Outcomes of surgical repair of double-chambered right ventricle. Ann Thorac Surg 2012;93:197–200.
[5] Patibandla S, Kyaw H. Double chambered right ventricle. StatPearls National Library of Medicine; 2019. Nobember 30.
[6] Barik R. Role of echocardiograghy in treating a case of double chamber right ventricle with delayed presentation. J Cardiovasc Echogr 2017;27:10–3.
[7] Yoshikazu HNTea. Repair of double-chambered right ventricle: surgical results and long-term follow-up. Ann Thorac Surg 2001;72:1520–2.
[8] Choi YJ, Park SW. Characteristics of double-chambered right ventricle in adult patients. Korean J Intern Med 2010;25:147–53.