Endocardial obliterative left atrial appendage closure by inverted purse-string plication

Yoshitsugu Nakamura, MD, PhD, Taisuke Nakayama, MD, PhD, Miho Kuroda, MD, Yuto Yasumoto, MD, and Chihiro Shirai, ME

ABSTRACT

Objective: To describe an endocardial obliterative left atrial appendage closure (LAAC) technique using inverted appendage purse-string plication added to 2-layer orifice closure and to evaluate anatomic and clinical outcomes in minimally invasive and robotic mitral surgery.

Methods: This retrospective study included consecutive patients who underwent robotic mitral valve surgery, or atrial septal defect repair with tricuspid intervention, with concomitant endocardial obliterative LAAC between April 2024 and June 2025. The technique inverts the distal half of the left atrial appendage (LAA), compacts it with a 3-0 barbed purse-string along an oblique line in the pectinate muscle, restores native orientation, then performs a 2-layer orifice closure with polypropylene sutures. Pre- and postoperative electrocardiogram-gated cardiac computed tomography (ECG-CT) was used to assess anatomy. The primary end point was complete closure, defined as absence of contrast filling within the LAA body in early and delayed phases. Analyses were descriptive.

Results: Twenty-four patients (median age, 71.5 years) underwent endocardial obliterative LAAC with the da Vinci system without conversion or intraoperative bleeding requiring intervention. There were no perioperative deaths, strokes, myocardial ischemic events, re-explorations, or left circumflex artery injuries. At 3 to 6 months, ECG-CT in all patients showed complete closure with no contrast inflow, residual lumen, pericardial effusion, and periappendage hematoma.

Conclusions: Endocardial obliterative LAAC using inverted appendage purse-string plication followed by 2-layer orifice closure is a simple, inexpensive, and safe adjunct to minimally invasive mitral surgery, achieving ECG-CT–confirmed complete anatomic closure in this early series and potentially enhancing the effectiveness of surgical LAAC. (JTCVS Techniques 2026;36:102268)

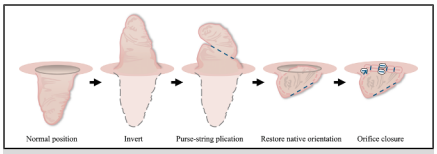

Obliterative LAAC using inverted appendage purse-string plication yields complete closure.

CENTRAL MESSAGE

Orifice-only endocardial LAA closure can leave small residual cavities, whereas this obliterative LAAC technique using inverted appendage purse-string plication yields complete closure.

PERSPECTIVE

Surgical LAAC performed concomitantly with cardiac surgery reduces long-term stroke risk. However, standard endocardial orifice-only closure can leave a residual stump or small perfused cavity on ECG-CT. An endocardial obliterative technique using inverted appendage purse-string plication added to routine orifice closure targets this failure geometry without added invasiveness or device cost.

Video clip is available online.

Concomitant left atrial appendage closure (LAAC) during cardiac surgery lowers the risk of ischemic stroke compared with surgery alone.[1] Endocardial LAAC with orifice closure from the left atrium is attractive because access is straightforward and the approach is economical. Its limitation is incomplete closure, which is detected by electrocardiogram-gated cardiac computed tomography (ECG-CT) in roughly one quarter of cases.[2] In our robot-assisted mitral program, double-layer entrance suturing produced a similar ~24% rate of late opacification on ECG-CT, typically as diffuse contrast filling of the appendage from minute suture-line leaks—the so-called "speech-bubble" sign.[3]

These observations led to a simple principle: rather than merely closing the orifice, we should achieve luminal obliteration by inverting the distal half of the left atrial appendage (LAA) and securing it with purse-string plication. We report

From the Department of Cardiovascular Surgery, Chibanishi General Hospital, Chiba, Japan.

Received for publication Nov 26, 2025; revisions received Jan 9, 2026; accepted for publication Jan 10, 2026; available ahead of print Jan 30, 2026.

Address for reprints: Yoshitsugu Nakamura, MD, PhD, Department of Cardiovascular Surgery, Chibanishi General Hospital, 107-1 Kanegasaku, Matsudo-city, Chiba 270-2251, Japan (E-mail: ystgnkmr@gmail.com).

2666-2507

Copyright © 2026 The Author(s). Published by Elsevier Inc. on behalf of The American Association for Thoracic Surgery. This is an open access article under the CC BY-NC-ND license (http://creativecommons.org/licenses/by-nc-nd/4.0/).

https://doi.org/10.1016/j.xjtc.2026.102268

Abbreviations and Acronyms

AF = atrial fibrillation
ECG-CT = electrocardiogram-gated cardiac computed tomography
LAA = left atrial appendage
LAAC = left atrial appendage closure

the steps of this endocardial obliterative LAAC and our early imaging and clinical outcomes.

METHODS

Study Design and Patient Population

This was a single-center, retrospective observational study conducted at Chibanishi General Hospital. We identified all consecutive adult patients who underwent minimally invasive or robotic mitral valve surgery with concomitant endocardial LAAC using the inverted purse-string obliterative technique between April 2024 and June 2025. The study was approved by the institutional review board of Chibanishi General Hospital (TGE02656-025) on November 5, 2024, which waived the requirement for individual written informed consent for this retrospective analysis of anonymized data.

Patient Selection and Exclusion Criteria

Patients were eligible if (1) they had a preoperative diagnosis of paroxysmal or chronic atrial fibrillation (AF) and an indication for surgical mitral valve intervention or atrial septal defect repair and tricuspid valve intervention and (2) if they were scheduled to undergo concomitant obliterative LAAC using the inverted purse-string obliterative technique. Demographic, echocardiographic, and operative variables were obtained from institutional cardiac surgery and imaging databases.

Imaging Protocol

Preoperative ECG-CT was used to quantify left atrial/LAA volumes, ostial size, morphology, and coronary proximity (Philips IntelliSpace Portal; slice thickness 0.8 mm, increment 0.4 mm; 75% cardiac phase). At 3 to 6 months, contrast-enhanced ECG-synchronized CT was obtained unless contraindicated. Both early and delayed phases were reviewed. The primary anatomical end point was complete closure of the LAA on postoperative ECG-CT, defined as the absence of any contrast filling within the LAA body in both early and delayed phases. The "speech-bubble" sign was defined as any focal or diffuse contrast pooling distal to an apparently closed LAA orifice on delayed-phase images.[3]

Surgical Technique

The procedure was performed concomitantly with mitral surgery through a right thoracic robotic approach in most cases. Cannulation and myocardial protection followed institutional routine. A 3-0 barbed suture (V-Loc, Medtronic plc) was used for plication and 3-0 and 4-0 polypropylene (PROLENE; Ethicon) were used for orifice closure. The procedure for obliterative LAAC is shown in Video 1 and Figure 1:

1. Inversion (Figure 1, *B*). Gently invert the LAA into the left atrium with atraumatic forceps, creating an intraluminal oblique cone that is shorter anteriorly and longer posteriorly.
2. Purse-string plication (Figure 1, *C*). Identify the midpoint of the short anterior aspect of the inverted cone and plan an oblique line toward the base. Obliquity facilitates "tucking" the distal cone into the proximal portion. As a rule of thumb, choose the line so that tissue volumes distal and proximal to it are roughly balanced. (Skin marking is optional and used only for demonstration in the video.) Along this line, place a purse-string with 3-0 barbed suture, taking partial-thickness bites confined to the pectinate muscle to reduce bleeding risk. Avoid full-thickness passes. Tighten sequentially to compact the distal cone.
3. Restore native orientation (Figure 1, *D*). Revert the LAA toward its anatomic position. The proximal half returns to native orientation, whereas the distal half remains inverted and secured by the purse-string, achieving luminal obliteration.
4. Two-layer orifice closure (Figure 1, *E*). Close the orifice with a horizontal-mattress layer followed by an over-and-over running layer using 4-0 polypropylene. At the ceiling of the orifice and at curvature changes, add a short reinforcing bite if in doubt. (In the video, we confirm from the epicardial side that the LAA shows a gentle concavity without distortion.)

Knicks and Pitfalls

Keep bites in the pectinate muscle to limit bleeding. Anticipate potential leak "hot spots" at the ceiling side of the start point and at bends in the suture line. In tall, slender

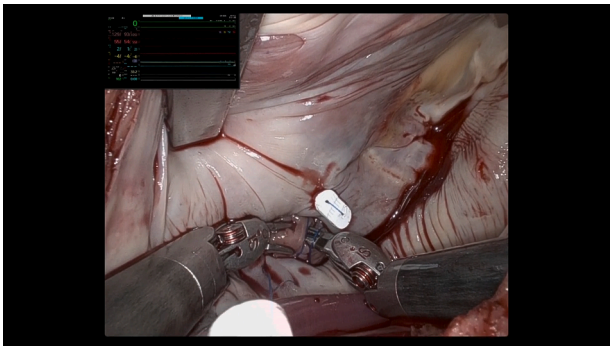

VIDEO 1. Planning of the obliterative LAAC. Video available at: https://www.jtcvs.org/article/S2666-2507(26)00075-1/fulltext.

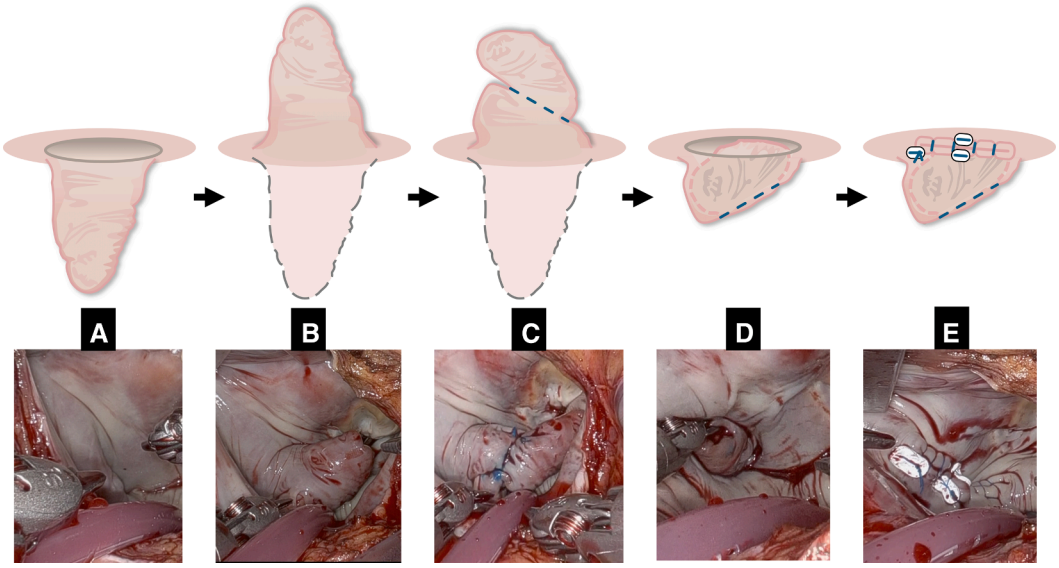

FIGURE 1. Steps of surgical technique for obliterative LAAC. A, Normal position; (B), inversion; (C), purse-string plication; (D), restoration of native orientation; (E), 2-layer orifice closure. *LAAC*, Left atrial appendage closure.

inverted cones, the plication line can be less oblique and nearly parallel to the base. Although no patients in this study cohort had LAA thrombus, in our subsequent experience we have encountered small thrombi that were carefully removed using suction and forceps before performing obliterative LAAC.

RESULTS

Between April 2024 and June 2025, 24 consecutive patients with AF associated with mitral valve disease or with atrial septal defect and tricuspid regurgitation underwent obliterative LAAC using the da Vinci surgical system (Intuitive Surgical, Inc). No adverse events—including bleeding, arrhythmia, myocardial ischemia, cardiac or noncardiac injury, stroke, or death—occurred. Notably, no left circumflex artery injury was observed during LAA closure.

All patients underwent postoperative ECG-CT. Demographics are summarized in Table 1. Median age was 71.5 years, 33% of patients were female, and the median body surface area was 1.58 m^2. In total, 25% had mild chronic kidney disease, but no patients were on dialysis. AF type was paroxysmal in 17% and long-standing persistent in 83%. Median $CHADS_2$ and CHA_2DS_2-VASc scores were 2 and 3, respectively. Median left ventricular ejection fraction was 61.5% and left atrial diameter 49.8 mm. In total, 92% had moderate-to-severe or severe mitral regurgitation and 46% had moderate-to-severe tricuspid regurgitation.

LAA anatomy is summarized in Table 2: cactus, 17%; chicken-wing, 63%; windsock, 13%; and cauliflower, 8.3%. Mean LAA width was 31.9 mm, and mean LAA volume 16.3 mL.

Operative details are shown in Table 3. A concomitant maze procedure is generally performed when the F-wave amplitude in lead V1 is $\geq$0.1 mV; conversely, the maze is avoided when the F wave is nearly flat and/or the ventricular rate is <50 beats per minute. In this series, 19 patients (79%) underwent a concomitant maze procedure according to the aforementioned institutional criteria. Obliterative LAAC did not interfere with intracardiac procedures including mitral valve surgery or maze procedure. No intraoperative bleeding requiring intervention occurred. Intraoperative transesophageal echocardiogram confirmed complete closure of LAA at the end of the surgery. There was no mortality, no stroke, and no bleeding event during the follow-up period (Table 4).

ECG-CT Assessment

All patients demonstrated complete closure with no contrast inflow into the LAA on delayed ECG-CT (Table 4 and Figure 2). No pericardial effusion or periappendage hematoma was seen. No injuries to adjacent structures, including the left coronary system, were identified.

DISCUSSION

Orifice-only endocardial closure can fail when a minute defect permits delayed contrast entry, diffusely reexpanding a residual lumen. By eliminating the intraluminal potential space, the obliterative technique ensures that—even if microscopic porosity remains at the orifice—there is no cavity to opacify, thereby preventing suture-line leak. The added step—inversion with purse-string plication—is simple. A further strength of this study is the systematic use of ECG-CT to confirm anatomic completeness, providing objective imaging validation beyond intraoperative

TABLE 1. Baseline characteristics of the present series (n = 24)

Variables	All patients (n = 24)
Age, y	71.5 (65-76.8)
Female	8 (33%)
Body surface area, m^2	1.58 (1.46-1.73)
Hypertension	15 (63%)
Diabetes mellitus	4 (17%)
Chronic obstructive pulmonary disease	1 (4%)
Chronic kidney disease	6 (25%)
Dialysis	0 (0%)
Congestive heart failure	17 (71%)
Cardiovascular implantable electronic device	0 (0%)
SSE (ischemic stroke/systemic embolization)	4 (17%)
Long-standing persistent AF	20 (83%)
Paroxysmal AF	4 (17%)
Low-voltage f wave (<0.2 mV)	2 (9%)
CHADS2 score ≥2	2 (1-2) 17 (71%)
CHA2DS2-VASc score ≥3	3 (2-3) 15 (63%)
Left ventricular ejection fraction, %	61.5 (56.8-68.6)
Left atrial diameter, mm	49.8 (42.8-54.9)
Mitral valve regurgitation (moderate-severe, or severe)	22 (92%)
Tricuspid valve regurgitation (moderate or greater than moderate)	51 (46%)

Data are presented as median (interquartile range) or n (%). *SSE*, Ischemic stroke/systemic embolization; *AF*, atrial fibrillation.

transesophageal echocardiography. In this series, no bleeding events occurred, and no CT-detectable hematoma or effusion was observed, supporting procedural safety.

The methodologic strength of this approach is that it obliterates the LAA lumen using the appendage itself while imposing minimal tension on LAA tissue. Nagaoka and colleagues[4] reported an inverted spiral plication that achieves vertical, spiral compaction of the LAA. However, it avoids linear orifice suturing, and the configuration may place sustained tension on the LAA tissue and at the entrance; postoperative surveillance—ideally with ECG-gated cardiac CT—is prudent. Intra-atrial complete

TABLE 2. Left atrial appendage anatomy by ECG-CT (n = 24)

Variables	All patients (n = 24)
LAA morphology	
Cactus	4 (17%)
Chicken wing	15 (63%)
Windsock	3 (13%)
Cauliflower	2 (8.3%)
LAA volume	
Width, mm	31.9 (28.8-39.4)
Volume, mL	16.3 (12-24)

Morphology according to Di Biase classification. Data are presented as median (interquartile range) or n (%). *ECG-CT*, Electrocardiogram-gated cardiac computed tomography; *LAA*, left atrial appendage.

TABLE 3. Concomitant procedures and operative details (n = 24)

Variables	All patients (n = 24)
Surgical procedure	
MV repair	17 (71%)
MV replacement	6 (25%)
Tricuspid valve annuloplasty	14 (58%)
ASD repair	2 (8.2%)
Maze surgery	19 (79%)
Left atrial plication	1 (4.1%)
Mitral valve, rigid or semi-rigid ring	1 (4.1%)
Mitral valve ring, flexible	19 (79%)
Ring or prosthetic valve size, mm	30.5 (28.8-34)
Intervention for intraoperative bleeding from LAA	0 (0%)

Data are presented as n (%) or median (interquartile range). Ring type and size refer to implanted annuloplasty ring or prosthetic valve as applicable. *MV*, Mitral valve; *ASD*, atrial septal defect; *LAA*, left atrial appendage.

TABLE 4. Early outcomes and ECG-CT assessment (n = 24)

Variables	All patients (n = 24)
Mortality	0 (0%)
Postoperative complication	
Stroke	0 (0%)
Bleeding event	0 (0%)
ECG-CT evaluation	
Complete closure	24 (100%)
Incomplete closure	0 (0%)
Speech babble sign	0 (0%)
Pericardial effusion	0 (0%)
Hematoma	0 (0%)
Postoperative rhythm	
Sinus rhythm	18 (75%)
Persistent AF	6 (25%)
Postoperative pharmacologic therapy at 3-6 mo after surgery	
DOAC	6 (25%)
Coumadin	4 (17%)
Antiplatelet drug	1 (4%)
Antiarrhythmic drug	6 (25%)
Beta blocker	15 (63%)
Statin	3 (13%)
ACE-I/ARB	5 (21%)
Follow-up, mo	5 (3-6)

Data are presented as n (%) or median (IQR). "Complete closure" denotes no contrast inflow into the LAA on delayed ECG-CT. Follow-up indicates the imaging/clinical assessment window (months). *ECG-CT*, Electrocardiogram-gated cardiac computed tomography; *AF*, atrial fibrillation; *DOAC*, direct oral anticoagulant; *ACE-I*, angiotensin-converting enzyme inhibitor; *ARB*, angiotensin receptor blocker.

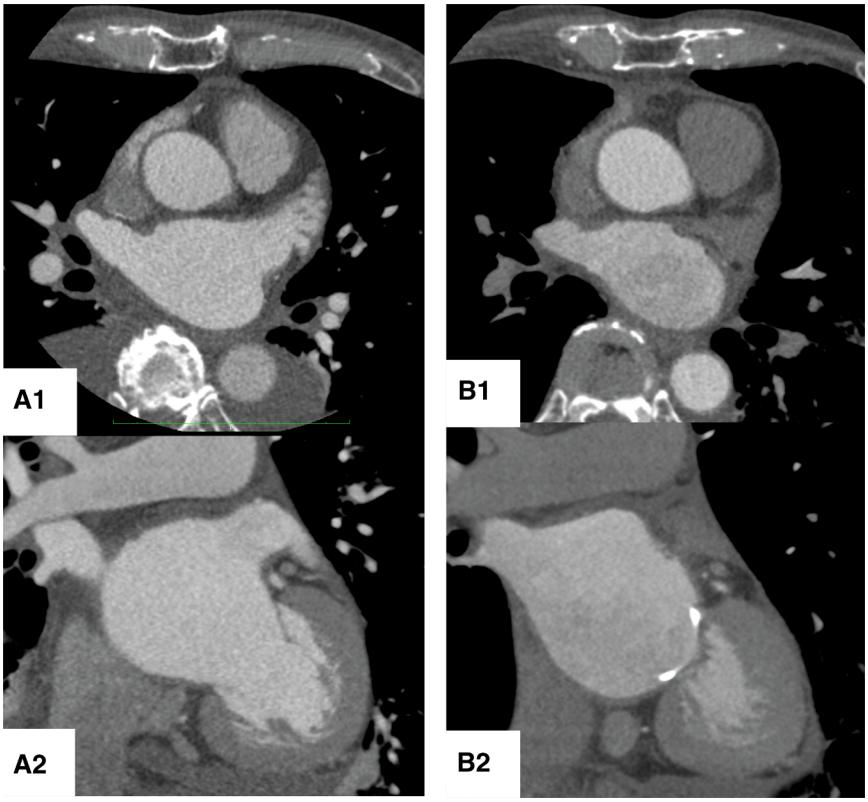

FIGURE 2. ECG-gated cardiac CT. Preoperative LAA axial view (A1) and coronal view (A2) and postoperative LAA. The LAA was completely closed. Axial view (B1) and coronal view (B2). *ECG-CT*, Electrocardiogram-gated cardiac computed tomography; *LAA*, left atrial appendage.

excision yields a stump-less result but carries a bleeding risk from a thin, variably trabeculated base,[5] and in robotic cases hemostasis after crossclamp removal can be challenging if bleeding arises from the appendage bed. Epicardial clipping provides high complete-closure rates, yet in right-chest mitral approaches transverse-sinus access can be limited, device size may be mismatched to the available space, and cost is an additional constraint.

In the present series, obliterative endocardial LAAC achieved complete closure irrespective of LAA morphology or size. Using the Di Biase categories—cactus, chicken-wing, windsock, and cauliflower—the distribution of morphologies appeared comparable with previous reports, supporting the generalizability of the technique across typical anatomic variants.[6] Mechanistically, inversion with purse-string plication obliterates the intraluminal potential space; completeness therefore does not depend on a perfectly linear orifice seal. Execution varies modestly with shape: when the inverted cone is tall and elongated, the plication line can be less obliquity—often nearly parallel to the base—simplifying compaction without compromising completeness. Size metrics in this series also fall within expected ranges, with reported LAA volumes of $\sim 3.4 \pm 1.1$ mL/m^2 in healthy controls[7] and $\sim 22 \pm 15$ mL in AF cohorts[8]; our mean of 16.3 mL lies squarely within the AF distribution. Taken together, morphology and size chiefly inform where the oblique line is planned and how deep the bites are taken in the pectinate muscle, but they do not determine feasibility or the likelihood of complete closure.

Large studies—most notably LAAOS III[1]—and several surgical series support concomitant LAAC[9,10] for stroke prevention, but confirmation of anatomic completeness has been rare. Endocardial entrance-suture techniques show $\sim$25% recanalization on ECG-CT.[2,3] Because previous trials demonstrated benefit without confirmed completeness, some effect likely occurred despite unrecognized recanalization. Future studies that compare CT-confirmed complete closure versus no LAAC may therefore reveal a larger stroke reduction. Within surgical endocardial obliterative LAAC should raise complete-closure rates and plausibly improve clinical effectiveness in programs favoring endocardial techniques.

Study Limitations

This was a single-center early experience with modest sample size; durability and clinical outcomes require longer follow-up.

CONCLUSIONS

Obliterative LAAC—distal-half inversion with purse-string plication followed by 2-layer orifice closure—is

simple, inexpensive, and safe. In this early series it achieved ECG-CT–confirmed complete closure without bleeding or adjacent-structure injury. The method suits robot-assisted or thoracoscopic mitral surgery, where additional ports and device costs are undesirable.

Conflict of Interest Statement

The authors reported no conflicts of interest.

The *Journal* policy requires editors and reviewers to disclose conflicts of interest and to decline handling or reviewing manuscripts for which they may have a conflict of interest. The editors and reviewers of this article have no conflicts of interest.

Declaration of Generative AI and AI-Assisted Technologies in the Writing Process

During the preparation of this work the authors used Chat GPT in order to translate from Japanese to English. After using this tool/service, the authors reviewed and edited the content as needed and take full responsibility for the content of the publication.

References

1. Whitlock RP, Belley-Côté EP, Paparella D, et al. Left atrial appendage occlusion during cardiac surgery to prevent stroke (LAAOS III). *N Engl J Med*. 2021; 384(22):2081-2091. https://doi.org/10.1056/NEJMoa2101897
2. Aryana A, Singh SM, Singh SK, et al. Association between incomplete surgical ligation of left atrial appendage and stroke and systemic embolization. *Heart Rhythm*. 2015;12(7):1431-1437. https://doi.org/10.1016/j.hrthm.2015.03.028
3. Nakayama T, Nakamura Y, Shukuya A, et al. Speech bubble sign—insights regarding incomplete left atrial appendage closure via electrocardiography-synchronized computed tomography in robotic surgery cases. *Interact Cardiovasc Thorac Surg*. 2025;40(10):ivaf172. https://doi.org/10.1093/icvts/ivaf172
4. Nagaoka E, Arai H, Mizuno T, et al. Innovative surgical left atrial appendage closure technique: early experience of inverted spiral closure technique. *Innovations (Phila)*. 2024;19(6):656-659. https://doi.org/10.1177/15569845241288564
5. Ghinescu M, Franke UFW, Ortega M, Hüther F, Rufa MI, Göbel N. Concomitant intra-atrial excision of the left atrial appendage during robotic-assisted minimally invasive cardiac surgery. *Front Cardiovasc Med*. 2023;10:1074777. https://doi.org/10.3389/fcvm.2023.1074777
6. Di Biase L, Santangeli P, Anselmino M, et al. Does the left atrial appendage morphology correlate with the risk of stroke in patients with atrial fibrillation? Results from a multicenter study. *J Am Coll Cardiol*. 2012;60(6):531-538. https://doi.org/10.1016/j.jacc.2012.04.032
7. Taina M, Vanninen R, Hedman M, et al. Left atrial appendage volume increased in more than half of patients with cryptogenic stroke. *PLoS One*. 2013; 8(11):e79519. https://doi.org/10.1371/journal.pone.0079519
8. Lee HJ, Seo J, Shim CY, et al. Left atrial appendage characteristics assessed with cardiac computed tomography in atrial fibrillation with severe mitral valve disease. *Yonsei Med J*. 2025;66(7):529-556. https://doi.org/10.3349/ymj.2024.0455
9. Chikwe J, Roach A, Emerson D, et al. Left atrial appendage closure during mitral repair in patients without atrial fibrillation. *J Thorac Cardiovasc Surg*. 2024; 168(1):86-93. https://doi.org/10.1016/j.jtcvs.2023.02.030
10. Elbadawi A, Ogunbayo GO, Elgendy IY, et al. Impact of left atrial appendage exclusion on cardiovascular outcomes in patients with atrial fibrillation undergoing coronary artery bypass grafting (from the National Inpatient Sample Database). *Am J Cardiol*. 2017;120(6):953-958. https://doi.org/10.1016/j.amjcard.2017.06.025

Key Words: left atrial appendage closure, endocardial closure, ECG-gated cardiac CT, inversion, plication, robotic surgery