Circulation Reports
Circ Rep 2026; 8: 391–399
doi:10.1253/circrep.CR-25-0276

ORIGINAL ARTICLE
Arrhythmia/Electrophysiology

Outcomes of Thoracoscopic Left Atrial Appendage Occlusion With or Without Concomitant Thoracoscopic Ablation

— Multicenter Retrospective Registry of 567 Patients in Japan —

Taisuke Nakayama, MD, PhD; Hiroshi Ito, MD, PhD; Shunsuke Sato, MD;
Seimei Kure, MD, PhD; Gentaku Hama, MD;
Masakazu Aoki, MD; Shinya Takahashi, MD, PhD

Background: Atrial fibrillation (AF) is a major risk factor for ischemic stroke, with >90% of thrombi in nonvalvular AF originating in the left atrial appendage (LAA). Thoracoscopic LAA occlusion (LAAO), with or without ablation, is a minimally invasive alternative to endocardial devices or anticoagulation, but multicenter data are limited.

Methods and Results: The Totally Thoracoscopic Left Atrial Appendage Occlusion Study (TT-LAAOS) is a multicenter Japanese registry of thoracoscopic LAAO in nonvalvular AF. From March 2018 to December 2024, 567 patients underwent the procedure at 6 institutions using stapler excision or epicardial clip. Outcomes included procedural success, anatomic closure, cerebrovascular events, and anticoagulant withdrawal. Mean age was 72 years; 63.5% had long-standing persistent AF. Median $CHADS_2$ and CHA_2DS_2 VASc scores were 2 and 4, respectively. Success was 99.8% with no intraoperative deaths; residual stumps >10 mm were found in 1.5%. At discharge, sinus rhythm was present in 45%. Anticoagulants were stopped in 15% immediately and 63% within 1 month. During 875.8 patient years of follow-up (median 13 months), freedom from stroke or transient ischemic attack was 99.5% (0.34/100 patient years), with no thromboembolic deaths.

Conclusions: Thoracoscopic LAAO, with or without ablation, is safe and effective for stroke prevention in AF, with high success, reliable closure, and very low midterm events.

Key Words: Atrial fibrillation; Left atrial appendage; Minimally invasive cardiac surgery; Stroke; Total thoracoscopic procedure

Atrial fibrillation (AF) is a prevalent arrhythmia affecting approximately 3% of the adult population, with its incidence expected to rise significantly in the coming decades.[1,2] AF increases the risk of stroke by 3–5-fold, and >90% of thrombi in nonvalvular AF originate from the left atrial appendage (LAA).[3,4]

To reduce stroke risk, various surgical techniques for LAA occlusion, including suture ligation, stapling, and excision, have been explored, but are limited by inadequate visualization, often resulting in residual LAA tissue or incomplete closure that sustains thromboembolic potential.[5–7] Thoracoscopic approaches address these shortcomings through enhanced visualization and precise device placement. More recently, clip-based occlusion has shown encouraging results, achieving safe and reliable closure in both open-heart[8] and thoracoscopic procedures.[9,10] In some centers, it is routinely combined with thoracoscopic AF ablation as part of the totally thoracoscopic maze (TT-maze) procedure.[11]

Based on this concept, thoracoscopic wide-antral ablation approaches have shown favorable remodeling and rhythm outcomes.[10] Technical refinements, such as the introduction of artificial pneumothorax, have further improved surgical exposure and procedural precision.[10] In the catheter-based field, wide-planar antral ablation has also demonstrated reverse remodeling benefits.[12] Additional visualization techniques, such as pacing-based maneuvers to enhance LAA delineation, have likewise been described in electro-

Received November 5, 2025; revised manuscript received November 9, 2025; accepted November 10, 2025; J-STAGE Advance Publication released online January 9, 2026 Time for primary review: 1 day

Department of Cardiovascular Surgery, Chiba-Nishi General Hospital, Chiba (T.N.); Department of Cardiovascular Surgery, Saiseikai Shimonoseki General Hospital, Yamaguchi (H.I.); Department of Cardiovascular Surgery, Yodogawa Christian Hospital, Osaka (S.S.); Department of Cardiovascular Surgery, Hiroshima University Hospital, Hiroshima (S.K., S.T.); Department of Cardiovascular Surgery, Sapporo Cardio Vascular Clinic, Sapporo Heart Center, Sapporo (G.H.); and Department of Cardiovascular Surgery, Matsumoto Kyouritsu Hospital, Nagano (M.A.), Japan

H.I. is a member of *Circulation Reports*' Editorial Team.

Mailing address: Taisuke Nakayama, MD, PhD, Department of Cardiovascular Surgery, Chiba-Nishi General Hospital, 107-1 Kanegasaku, Matsudo, Chiba 270-2251, Japan. email: taisuke.nakayama0129@gmail.com

All rights are reserved to the Japanese Circulation Society. For permissions, please email: cr@j-circ.or.jp

ISSN-2434-0790

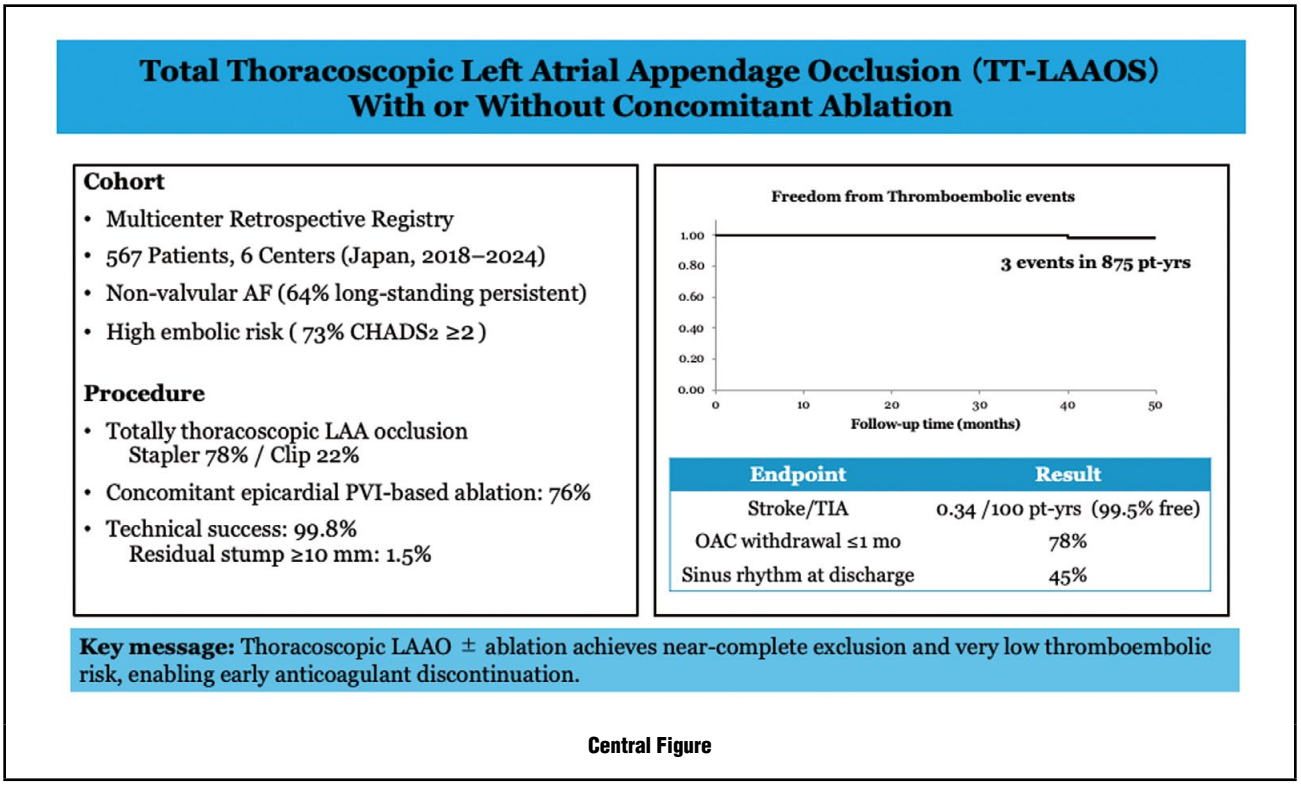

Central Figure

physiologic practice.[13] Thus, despite differences in procedural modality, both thoracoscopic and catheter-based strategies converge on the principle of wide-area antral isolation as a key determinant of atrial remodeling.

In a European multicenter cohort, van Laar et al. reported favorable outcomes of thoracoscopic LAA clipping, with no intraoperative complications and a cerebrovascular event rate of 0.5/100 patient-years.[9] However, their analysis was limited to a single device type (clip), lacked systematic rhythm evaluation, and provided little information on postoperative anticoagulation management. Consequently, the specific contribution of LAA closure to stroke prevention remains uncertain, and the generalizability of those findings to broader practice settings is unclear. In Japan, the 2020 JCS Guidelines for the Pharmacotherapy of Cardiac Arrhythmias recognized LAA closure as a therapeutic option in selected high-risk patients,[14] and thoracoscopic LAA occlusion (LAAO) has been covered by the national insurance system since 2022. These developments underscore the need for contemporary, real-world evidence from Japanese clinical practice.

Accordingly, the present Totally Thoracoscopic Left Atrial Appendage Occlusion Study (TT-LAAOS) was conducted to evaluate the safety, efficacy, and reproducibility of thoracoscopic LAAO (with or without concomitant thoracoscopic ablation) across 6 institutions in Japan. This registry incorporated both stapler- and clip-based techniques and systematically captured postoperative imaging, rhythm outcomes, and anticoagulation management. We hypothesized that this minimally invasive approach could provide a durable and broadly applicable stroke-prevention strategy for patients with AF. To our knowledge, TT-LAAOS represents the largest multicenter registry of thoracoscopic AF surgery in Japan.

Methods

Study Design and Ethical Approval

This study was designed as a retrospective, multicenter observational registry including 567 patients who underwent thoracoscopic LAAO between March 2018 and December 2024 at 6 Japanese institutions: Chiba-Nishi General Hospital, Saiseikai Shimonoseki General Hospital, Yodogawa Christian Hospital, Hiroshima University Hospital, Sapporo Heart Center, and Matsumoto Kyouritsu Hospital. Written informed consent was given by all patients. The protocol was approved by the institutional review boards of all participating institutions, with Chiba-Nishi General Hospital as the lead center (Approval No. TGE02505-025).

Patient Selection

Eligible patients had AF (paroxysmal, persistent, or long-standing persistent) and were considered for thoracoscopic LAAO if they had either contraindications to oral anticoagulants (OACs) or insufficient OAC efficacy. Contraindications included major or clinically relevant non-major bleeding (International Society on Thrombosis and Haemostasis (ISTH) criteria), unsafe requirement for concomitant antiplatelet therapy, or unstable anticoagulation control (labile INR with vitamin K antagonists or renal dysfunction affecting direct OAC (DOAC) dosing). Poor adherence was considered only when persistent despite appropriate supervision. Insufficient OAC efficacy was defined as ischemic stroke occurring during therapeutic anticoagulation after exclusion of non-cardioembolic causes.

All cases were reviewed by multidisciplinary AF Heart Teams (surgeons, electrophysiologists, neurologists),

and thoracoscopic LAAO was chosen as an alternative to percutaneous closure or continued anticoagulation according to each patient's background, bleeding risk, and preference.

Definitions

Stroke was defined as a new neurological deficit lasting ≥24 h with imaging confirmation. Transient ischemic attack (TIA) was defined as symptoms <24 h without infarction. Major bleeding followed ISTH criteria: fatal bleeding, critical-site bleeding (e.g., intracranial, pericardial), or ≥2 g/dL hemoglobin drop or transfusion ≥2 units.[15]

Surgical Approach and Technique

Procedures were performed under general anesthesia with single-lung ventilation using a standard 4-port thoracoscopic approach.[15] In selected cases, carbon dioxide insufflation was used to create artificial pneumothorax and enhance exposure.[10]

LAA Closure Technique

One of 2 closure techniques were used according to institutional preference. (1) Cut-and-Staple Method: A linear stapler (ECHELON FLEX, ETHICON, USA) was applied flush to the base of the LAA. In cases of residual pouch, reinforcement with a loop technique was performed to ensure complete exclusion. (2) AtriClip Application: After sizing, the AtriClip device (AtriCure, USA) was positioned parallel to the aortic root under thoracoscopic visualization. Intraoperative transesophageal echocardiography (TEE) confirmed complete occlusion and absence of residual flow.

Technical success was defined as intraoperative confirmation of complete exclusion.

Thoracoscopic Rhythm Control Strategy

The decision to perform concomitant thoracoscopic rhythm control procedures was based on institutional protocols and patient characteristics. Patients with long-standing AF (>10 years) or multiple prior catheter ablations, in whom restoration of sinus rhythm was deemed unlikely, typically underwent LAA closure alone.

In eligible patients, thoracoscopic epicardial ablation was performed following successful LAA closure using bipolar radiofrequency devices (Isolator Synergy Clamps and Transpolar Pen, AtriCure, USA) to achieve pulmonary vein isolation. In selected cases, en bloc isolation of the left pulmonary veins and LAA was performed as a single anatomical unit. Additional lesions, such as box lesions encompassing the posterior left atrial wall, were created at the discretion of each institution to optimize rhythm control outcomes.

Postoperative Management and Follow-up

Antithrombotic Regimen OAC (VKA or DOAC) was typically resumed on postoperative day 0–1 after hemostasis. In high bleeding-risk patients, OAC was discontinued immediately; in others, cessation was considered after imaging-confirmed LAA exclusion at ~1 month. Continuation was required when other indications existed (e.g., prior venous thromboembolism, mechanical valve) or when embolic risk outweighed bleeding risk.

Thoracoscopic LAAO was primarily performed for stroke prevention, and OAC discontinuation was regarded as a secondary, patient-specific outcome rather than a predefined endpoint. In patients with contraindications to long-term anticoagulation (e.g., prior gastrointestinal or intracranial bleeding), withdrawal was considered appropriate once closure had been verified. Decisions regarding anticoagulation discontinuation were made independently of residual AF status or sinus rhythm restoration. Single antiplatelet therapy was permitted at physician discretion.

Imaging Surveillance Transthoracic echocardiography (TTE) was performed before discharge to assess pericardial effusion and residual flow. Contrast-enhanced, ECG-gated cardiac computed tomography (CT) was recommended at approximately 1 month postoperatively to evaluate stump depth and morphology. Incomplete closure was predefined as a residual LAA stump ≥10 mm on CT or Doppler-detectable residual flow on TTE.

Postoperative imaging (TTE or CT) was omitted only when intraoperative thoracoscopic inspection and TEE provided clear evidence of complete LAA exclusion, with a well-defined closure line confirmed under direct vision. Anatomic closure was adjudicated primarily by CT; if unavailable, TTE Doppler was used.

Rhythm and Clinical Follow-up A 12-lead ECG was obtained at discharge and routine visits. Holter or patch monitoring was performed only when clinically indicated. Follow-up included cerebrovascular events, major bleeding, rehospitalization, and death verified by site investigators.

Endpoints Postoperative endpoints included: (1) anatomic success, (2) cerebrovascular events, (3) OAC discontinuation after imaging-verified exclusion, and (4) periprocedural and late complications.

Statistical Analysis

Continuous variables are reported as median [interquartile range (IQR)] and categorical variables as counts (%). Time-to-event outcomes included (1) all-cause death and (2) composite cerebrovascular endpoint (ischemic stroke, hemorrhagic stroke, or TIA). Kaplan-Meier curves were used with censoring at last follow-up, and incidence rates were calculated per 100 patient-years.

Results

Patients' Characteristics

Between March 2018 and December 2024, 567 patients underwent thoracoscopic LAAO (**Table 1**). Median age was 72 years [65–78], and 25% were women. AF type was paroxysmal in 29.1%, persistent in 7.9%, and long-standing persistent in 63.5%; AF duration exceeded 10 years in 25%. This relatively low rate reflects the inclusion of many patients with advanced or long-standing AF (39% had AF duration ≥6 years and 25% >10 years), for whom catheter ablation is often considered less effective or not indicated. In total, 42% had a history of ischemic stroke. Median $CHADS_2$ and CHA_2DS_2-VASc scores were 2 [1–4] and 4 [2–5], respectively; 72.8% and 74.3% met high-risk thresholds (≥2 and ≥3). Preoperative TTE showed moderate-to-severe mitral regurgitation in 5.4% and left ventricular ejection fraction <50% in 15%. Median left atrial diameter was 44.2 mm [39.2–50] (**Table 2**).

Indications for Surgery

Among the 567 patients, the leading indication for thoracoscopic LAAO was prevention of recurrent systemic embolization (n=239, 42%). Of these, 232 patients (41%) had a history of ischemic stroke, and 7 patients (1.2%) had peripheral or mesenteric arterial embolism. Other

Table 1. Baseline Patient Characteristics

Variables	
Age (years)	72 (65–78)
Female sex	142 (25%)
Body surface area, m^2	1.7 (1.56–1.82)
Hypertension	397 (70%)
Diabetes mellitus	126 (22%)
Chronic kidney disease	193 (34%)
Dialysis	18 (3.1%)
Cardiovascular implantable electronic device	33 (5.8%)
SSE (ischemic stroke/systemic embolization)	238 (42%)
Duration of AF (years)	
<1	109 (19.2%)
1–5	162 (28.6%)
6–10	79 (13.9%)
>10	142 (25%)
Unknown	75 (13.2%)
Type of AF	
Paroxysmal	165 (29.1%)
Persistent	45 (7.9%)
Long-standing persistent	360 (63.5%)
CLBBB	13 (2.3%)
CRBBB	47 (8.3%)
$CHADS_2$ score	2 (1–4)
≥2	413 (72.8%)
CHA_2DS_2-VASc score	4 (2–5)
≥3	421 (74.3%)
HAS-BLED score	2 (1–3)
≥3	207 (36.5%)
Prior catheter ablation	90 (15.8%)
Prior cardiovascular surgery	5 (0.9%)
ASD closure	3
Bentall operation	1
CABG	1
Prior thoracic surgery (e.g., lung resection)	6 (1.1%)

Data are presented as median (interquartile range) or n (%). $CHADS_2$, CHA_2DS_2-VASc, and HAS-BLED scores were defined according to standard criteria. $CHADS_2$ (congestive heart failure, hypertension, age 75 years, diabetes and stroke); CHA_2DS_2-VASc (congestive heart failure, hypertension, age 75 years, diabetes, stroke, vascular disease, age 65 years and sex category); HAS-BLED (Hypertension: systolic blood pressure >160 mmHg; Abnormal renal and/or liver function: (1 point each; chronic dialysis, renal transplant, or serum creatinine ≥200 μmol/L (chronic liver disease (e.g., cirrhosis) or significant hepatic derangement) Stroke: history of stroke; Bleeding: history of bleeding or a predisposition to bleeding; Labile INR: International Normalized Ratio (INR) <60% of the time; Elderly: age >65 years; Drugs and/or alcohol: concomitant use of antiplatelet/NSAID drugs or excessive alcohol consumption). AF, atrial fibrillation; ASD, atrial septal defect; CABG, coronary artery bypass graft; CLBBB, complete left bundle branch block; CRBB, complete right bundle branch block.

Table 2. Preoperative Findings From Transthoracic Echocardiography

Variables	
Left ventricular ejection fraction, %	61 (56–65)
>50%	483 (85%)
<50%	84 (15%)
Left atrial diameter, mm	44.2 (39.2–50.0)
Mitral valve regurgitation	
None	23 (4%)
Trace	168 (30%)
Mild	345 (58%)
Moderate	27 (4.7%)
Moderately severe	4 (0.7%)
Tricuspid valve regurgitation	
None	19 (3%)
Trace	184 (32%)
Mild	309 (54%)
Moderate	43 (7.6%)
Moderately severe	12 (2.1%)

Values are expressed as median (interquartile range) or n (%).

indications included high bleeding risk under anticoagulation, concomitant rhythm surgery for AF, and patient preference after multidisciplinary discussion (**Table 3**).

Operative Findings

The procedure was completed thoracoscopically in 98.6%; limited thoracotomy was required in a minority due to adhesions. LAAO alone was performed in 24% (n=136) and concomitant rhythm surgery in 76%. Overall LAA closure success was 99.8%; 1 case was aborted because of severe adhesions. Staplers were used in 78% and epicardial clips in 22% (**Table 3**). There were no intraoperative deaths. Conversion to thoracotomy/sternotomy for bleeding occurred in 6/567 (1.1%), with bleeding sources including the left atrial wall (n=2), pulmonary artery (n=1), pulmonary vein (n=1), and chest wall or port site (n=2).

A total of 20 patients (3.5%) received a perioperative blood transfusion, most commonly due to preexisting anemia or intraoperative blood loss: 14 patients received transfusion for preoperative anemia without evidence of surgical bleeding, and 6 corresponded to those who required re-thoracotomy. All bleeding cases were successfully managed, and no bleeding-related deaths occurred.

Postoperative Outcomes

There were no in-hospital deaths. Median postoperative stay was 6 days [5–9]. At discharge, sinus rhythm was documented on 12-lead ECG in 45% of patients (**Table 4**).

Imaging Findings

Postoperative CT was performed in 330/567 patients (58%). Complete exclusion with no residual stump was confirmed in 315/330 (95.5%; 55.6% of total cohort), stump <10 mm in 10/330 (3.0%), and stump ≥10 mm in 5/330 (1.5%), all after stapling. TTE was performed in 439/567 (77%); no residual flow was observed in 433/439 (98.6%; 76.4% of total cohort), and persistent flow in 6/439 (1.4%), all after stapling (**Table 4**).

Anticoagulation Management

Anticoagulation was continued when other indications existed or when embolic risk outweighed bleeding risk. Immediate postoperative OAC discontinuation occurred in 15% (n=86), and an additional 63% (n=357) had discontinued by 1 month after imaging-verified exclusion.

Cerebrovascular Events and Follow-up

During 893.7 patient-years of follow-up (median 13 months

Table 3. Procedural Outcomes of Patients Undergoing Thoracoscopic Surgical Strategies Incorporating LAA Closure

Variables	
Indications	
Prevention of recurrent systemic embolization	239 (42%)
Ischemic stroke	232 (41%)
Non-cerebral systemic embolization	7 (1.2%)
Discontinuation of anticoagulation therapy	127 (22%)
Recurrence AF after catheter ablation	74 (13%)
Surgical approach	
Thoracoscopy	559 (98.6%)
Thoracoscopy + small thoracotomy	8 (1.4%)
Surgical technique	
LAAO alone	136 (24%)
LAAO + BOX isolation	167 (29%)
LAAO + bilateral PV isolation	152 (27%)
LAAO + hemi–lateral PV isolation	91 (16%)
Operation time (min)	105 (74.5–138)
Blood transfusion	20 (3.5%)
Rate of successful LAA closure	566 (99.8%)
LAA closure method	
ECHELON FLEX Powered ENDOPATH Stapler 60	431 (76%)
ECHELON 3000	10 (1.8%)
AtriClip	
50 mm	6 (1.1%)
45 mm	33 (5.8%)
40 mm	57 (10%)
35 mm	17 (3.0%)
Another	12 (2.1%)
Perioperative complications	
Death	0 (0%)
Conversion to thoracotomy/sternotomy for bleeding	6 (1.1%)
Stroke	1 (0.2%)
Coronary injury	0 (0%)
Phrenic nerve palsy	3 (0.5%)
De novo pacemaker implantation	3 (0.5%)
Surgical site infection	2 (0.4%)
Requiring cardiopulmonary bypass	10 (1.8%)

Data are presented as median (interquartile range) or n (%). AF, atrial fibrillation; LAA, left atrial appendage; LAAO, LAA occlusion; PV, pulmonary vein.

Table 4. Early Postoperative Outcomes After Thoracoscopic Surgical Strategies Incorporating LAA Closure

Variables	
Postoperative hospital stay (days)	6 (5–9)
Hospital deaths	0
Rhythm status following surgery	
Sinus rhythm maintained postoperatively	256 (45%)
Sinus rhythm initially maintained, followed by recurrence of AF	76 (13%)
Persistent AF postoperatively	209 (37%)
Pacemaker rhythm before surgery	9 (1.6%)
Pacemaker implanted after surgery (including delayed implantation)	5 (0.9%)
Postoperative cardiac CT performed	330 (58%)
No residual left atrial appendage (LAA)	315 (96%)
Residual LAA stump <10 mm	10 (3.0%)
Residual LAA stump ≥10 mm	5 (1.5%)
Stapler-based closure (among ≥10 mm stump cases)	5/5
Postoperative transthoracic echocardiography	439 (77%)
No detectable LAA flow	433 (98.6%)
Detectable LAA flow	6 (1.4%)
Stapler-based closure (among flow-positive cases)	6/6
Postoperative anticoagulant therapy	
Discontinued immediately post-op	86 (15%)
Continued for ~1 month, then discontinued	357 (63%)
Continued post-op indefinitely	124 (22%)
Postoperative antiplatelet therapy	96 (17%)

Data are presented as median (interquartile range) or n (%). AF, atrial fibrillation; LAA, left atrial appendage.

[5–27]), overall survival was 98.5%; 13 deaths occurred, corresponding to an event rate of 1.46/100 patient-years. Causes included malignancy (n=3), pneumonia (n=3), cerebral hemorrhage (n=1), heart failure (n=2), and senility/unknown (n=4); no embolic deaths occurred (**Figure A**).

During 875.8 patient-years, freedom from thromboembolic events (the composite cerebrovascular endpoint: ischemic stroke, hemorrhagic stroke, or TIA) was 99.5%, corresponding to an event rate of 0.34/100 patient-years (**Figure B**). A total of 3 thromboembolic events were documented: (1) 74-year-old man ($CHADS_2$=3) with ischemic stroke at 40 months despite ongoing OAC and no residual LAA; (2) 84-year-old woman ($CHADS_2$=5) with early postoperative stroke (no postoperative imaging available); (3) 75-year-old man ($CHADS_2$=2) who developed acute lower limb arterial embolism 5 months after OAC cessation due to bleeding and renal dysfunction; postoperative CT had shown a residual LAA stump <10 mm.

Discussion

This study was a retrospective, multicenter registry rather than a prospective trial with a standardized protocol. Therefore, the findings primarily reflect real-world practice patterns and observed event rates, and causal inference should be made cautiously. Thoracoscopic LAAO in this registry was performed as part of a comprehensive treatment strategy for AF, rather than as an isolated procedure aimed solely at anticoagulation withdrawal. Many patients had prior thromboembolic events despite ongoing OAC therapy, and the procedure was implemented within a multidisciplinary management framework including rhythm control and individualized anticoagulation. Accordingly, the favorable cerebrovascular outcomes observed likely reflect the combined effects of LAAO and adjunctive therapy, rather than the exclusive efficacy of LAA closure itself. Nevertheless, these data provide important insights into the safety, procedural feasibility, and early cerebrovascular outcomes of thoracoscopic LAAO in contemporary Japanese practice.

In 2013, Ohtsuka et al. first demonstrated the feasibility of thoracoscopic epicardial LAA closure in patients with AF.[16] This technique allows complete exclusion of the

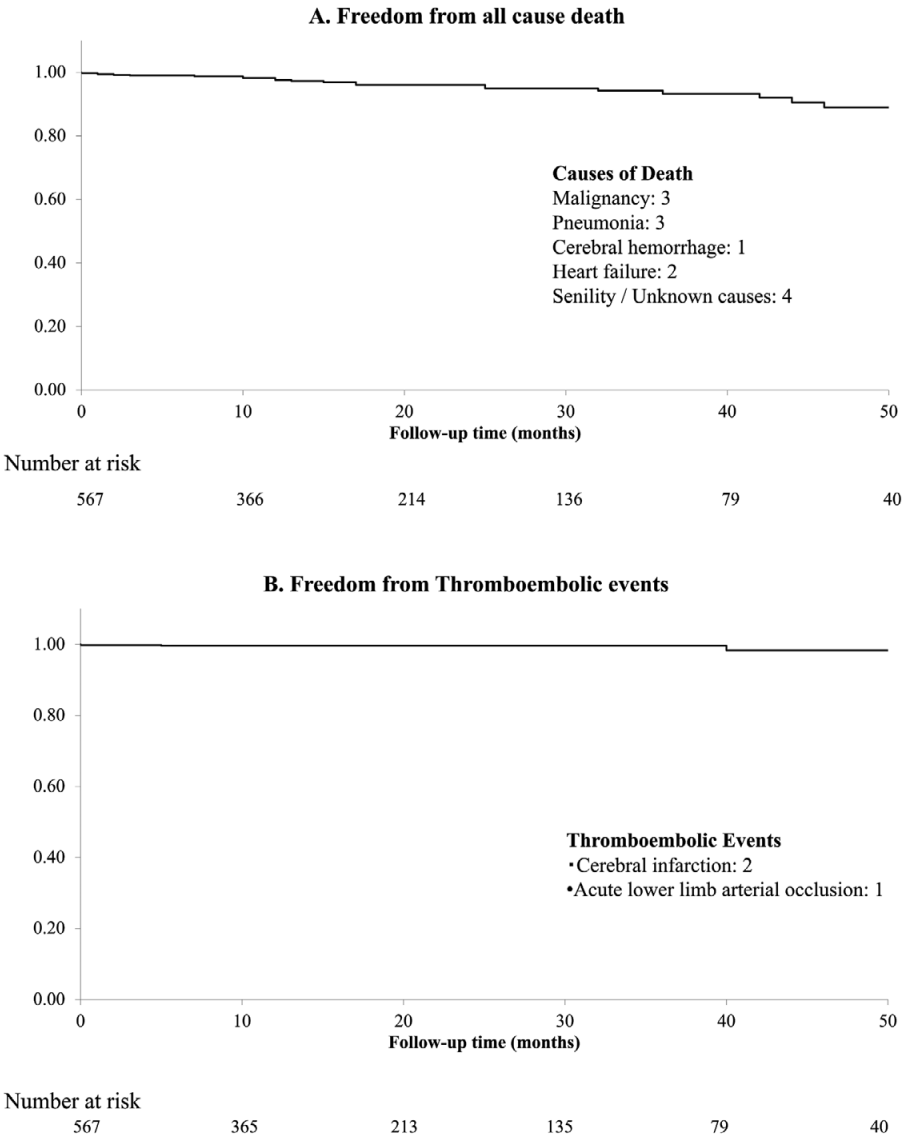

Figure. Kaplan-Meier curves for survival and freedom from thromboembolic events. (**A**) Freedom from all-cause death during follow-up (893.7 patient-years). (**B**) Freedom from composite thromboembolic events (ischemic stroke, hemorrhagic stroke, or transient ischemic attack) during follow-up (875.8 patient-years).

LAA under direct thoracoscopic visualization, regardless of its morphology, while avoiding intracardiac foreign material. These features potentially preserve atrial function and facilitate anticoagulant withdrawal. Although early experiences were limited to small, single-center reports with short follow-up, they established the foundation for minimally invasive surgical strategies for stroke prevention in AF.[11,16]

In April 2022, Japan became the first country to provide national insurance coverage for thoracoscopic LAA closure (procedure code K594-4), leading to its rapid clinical dissemination. Against this background, the TT-LAAOS represents the first multicenter, real-world evaluation of thoracoscopic LAA closure in Japan and the largest cohort reported to date. This registry was designed to assess safety, efficacy, and procedural reproducibility in contemporary practice. Surgical indications reflected multidisciplinary decision-making based on each patient's bleeding risk, anticoagulation intolerance, or prior thromboembolic history. Although this heterogeneity may limit uniform interpretation, it mirrors the practical patient population encountered in real-world Japanese clinical settings.

Van Laar et al. reported excellent results from a European multicenter cohort of 222 patients undergoing thoracoscopic LAA clipping, with no intraoperative or clip-related complications and a cerebrovascular event rate of 0.5/100 patient-years during 20 months of follow-up.[9] In our registry, comparable outcomes were achieved, with high anatomic closure rates and no intraoperative deaths, underscoring the procedural reliability of thoracoscopic

LAAO in a real-world multicenter setting.

Unlike the European series, which exclusively employed clips,[9] our cohort included both stapler- (78%) and clip-based (22%) techniques. Although the efficacy of staplers has been questioned in earlier sternotomy-based studies,[6,7] those results likely reflected limited visualization rather than intrinsic device inferiority. In the thoracoscopic approach, direct visualization enables precise stapler placement, and when residual pouches are identified, intraoperative reinforcement with a loop technique ensures complete exclusion.

All residual stumps were ≥10 mm after stapling, but likely reflects imaging detectability rather than true procedural difference. Because staplers leave no metallic artifacts, the staple line is clearly visualized on CT, whereas clips may obscure small residuals. Thus, apparent differences in residual detection should be interpreted with caution. No additional complications were reported from intraoperative reinforcement maneuvers.

Clip-based closure has the benefit of avoiding tissue transection and potentially reducing bleeding risk, though at higher device cost. In our series, re-exploration for bleeding occurred in 6 patients (1.1%); all successfully managed without deaths. Given that thoracoscopic LAAO is performed on the beating heart without cardiopulmonary bypass, such bleeding risk is inherent but acceptable. With accumulated experience and standardized training, the procedure can be performed safely and reproducibly.

The WATCHMAN™ device (Boston Scientific) was developed as an alternative to long-term anticoagulation for nonvalvular AF. Its efficacy was demonstrated in the PROTECT AF and PREVAIL trials, showing non-inferiority to warfarin for stroke prevention and reduced bleeding risk, leading to approval in Japan in 2019.[15,17]

The next-generation WATCHMAN FLX™, approved in 2021, expanded anatomical applicability and further reduced device-related complications. In the PINNACLE FLX trial, device-related thrombus (DRT) occurred in 1.8%, with complete closure in ~90% and all residual leaks <3 mm on core-lab TEE.[18] Those results confirmed low DRT rates and substantial reduction of peri-device leaks (PDL), although even small PDLs (≤5 mm) have been associated with increased thromboembolic risk. In a contemporary Japanese registry (OCEAN-LAAC), procedural and midterm outcomes with the WATCHMAN FLX were favorable and comparable to the prior 2.5 device, supporting its widespread adoption in Asian practice.[19] Furthermore, zero-contrast protocols have enabled safe LAAC even in patients with advanced chronic kidney disease, broadening its applicability in real-world practice.[20] Feasibility and a favorable safety profile in hemodialysis patients have also been demonstrated in a contemporary Japanese cohort.[21] Moreover, a contrast-free WATCHMAN FLX workflow has recently been reported, highlighting further procedural refinement for patients in whom iodinated contrast is undesirable.[22]

In contrast, thoracoscopic epicardial closure excludes the LAA externally without leaving intracardiac foreign material, thereby eliminating the DRT and PDL risks inherent to endocardial devices. This anatomical distinction represents a major conceptual advantage, potentially enabling both durable thromboembolic protection and freedom from long-term antithrombotic therapy.[11,23] Taken together, these observations position thoracoscopic epicardial approaches not only as mechanical closure techniques, but as biologically informed interventions that address both thromboembolic risk and arrhythmogenic substrate.[24]

Although both epicardial and endocardial strategies remain valuable, their indications differ. The present study did not aim to determine superiority but provide real-world evidence of the feasibility, safety, and early cerebrovascular outcomes of thoracoscopic LAA closure in contemporary Japanese practice. Prospective comparative studies are required to establish relative effectiveness.

The principal objective of LAA closure is stroke prevention in AF, but minimizing bleeding risk through withdrawal of antithrombotic therapy is an equally important goal. Current guidelines generally recommend continued anticoagulation after LAA exclusion in high-risk patients, reflecting concerns about asymptomatic AF recurrence and embolic sources beyond the LAA.[3] Nevertheless, as >90% of thrombi in nonvalvular AF arise from the LAA,[4] exclusion may provide a therapeutic option for patients with contraindications to OACs.

Antaki et al. reported that nearly all patients undergoing clip-based closure discontinued OACs, with only 1 exception (CHA_2DS_2-VASc=9), and among 108 patients with prior gastrointestinal bleeding, recurrent bleeding occurred in only 2 cases without subsequent cerebrovascular events.[23] Similarly, Ohtsuka et al. observed no thromboembolic events during a mean follow-up of 16 months in 21 patients undergoing thoracoscopic closure alone.[11]

In our cohort, anticoagulation was discontinued in 15% immediately postoperatively and in another 63% within 1 month, mainly due to prior bleeding, unstable INR, renal impairment, or concurrent cancer therapy. During follow-up, 3 ischemic events occurred, 2 of which developed despite ongoing OAC and were inconsistent with cardiogenic embolism.

At present, no consensus exists regarding the optimal criteria for OAC discontinuation after LAA closure. Our findings suggest that safe withdrawal may be feasible in selected patients, but prospective studies are needed to establish evidence-based protocols. These data provide contemporary evidence from Japan and may help guide future iterations of the JCS guideline recommendations.

Study Limitations

This study has several limitations inherent to its retrospective, multicenter design. Because participating institutions used non-uniform follow-up schedules and imaging or rhythm evaluation protocols, certain cerebrovascular or bleeding events may have been underreported. Patient selection was determined by multidisciplinary AF teams without standardized inclusion criteria, introducing potential selection bias. Moreover, postoperative anticoagulation management and imaging protocols were not unified, and detailed data regarding anticoagulant type, duration, and withdrawal timing were incomplete.

Not all patients underwent postoperative ECG-gated CT or TTE, limiting uniform assessment of anatomical closure. However, intraoperative TEE and thoracoscopic inspection confirmed complete exclusion in most cases, and additional imaging was deemed unnecessary. Routine rhythm monitoring (e.g., Holter or patch ECG) was not mandated, possibly leading to underestimation of asymptomatic AF recurrences.

The small number of thromboembolic events precluded subgroup analyses and limited the precision of survival

estimates. Therefore, the results should be regarded as descriptive and hypothesis-generating rather than confirmatory. Despite these limitations, this registry, the largest Japanese multicenter cohort of thoracoscopic LAA closure, provides valuable real-world evidence of procedural feasibility and early safety. Future prospective studies with standardized protocols and extended follow-up are warranted.

Conclusions

Thoracoscopic surgical strategies incorporating LAA closure were shown to be feasible and safe, achieving durable anatomical exclusion with a low incidence of stroke during follow-up. This first multicenter, real-world study from Japan confirms the reproducibility of the thoracoscopic approach and its applicability across diverse clinical settings. The epicardial technique offers a promising alternative for stroke prevention in patients with AF, particularly those at high thromboembolic risk who are unsuitable for long-term anticoagulation.

Despite the inherent limitations of this retrospective registry, these findings provide valuable real-world evidence supporting the procedural safety and clinical potential of thoracoscopic LAA closure. Further prospective studies are warranted to validate its long-term safety, efficacy, and contribution to stroke prevention.

Acknowledgments

The authors gratefully acknowledge the contributions of the surgical teams, research coordinators, and clinical staff at Chiba-Nishi General Hospital, Saiseikai Shimonoseki General Hospital, Yodogawa Christian Hospital, Hiroshima University Hospital, Sapporo Heart Center, and Matsumoto Kyouritsu Hospital for their dedicated support in data collection and patient management.

Funding

Not applicable.

Disclosures

H.I. is a member of *Circulation Reports*' Editorial Team.

Conflict of Interest

None declared.

Competing Interests

The authors declare that there are no competing interests.

Author Contributions

T.N. and S.S. conceived and designed the study. T.N., H.I., S.S., S.K., G.H., and M.A. collected clinical data from the participating institutions. T.N. performed the statistical analysis and drafted the manuscript. S.T. provided critical revision and supervision, and contributed major intellectual input and advice regarding key aspects of the manuscript. All authors contributed to interpretation of the data, approved the final version of the manuscript, and agree to be accountable for all aspects of the work.

Ethics Approval and Consent to Participate

The study protocol was approved by the institutional review boards of all participating institutions (Approval No. TGE02505-025; June 3, 2024), and written informed consent was given by all patients.

Consent for Publication

Not applicable.

IRB Information

The protocol was approved by the Institutional Review Board of Chiba-Nishi General Hospital (Approval No. TGE02505-025; June 3, 2024) and by the ethics committees of all participating institutions. The study was conducted in accordance with the Declaration of Helsinki. Written informed consent was given by all patients.

Data Availability Statement

The data underlying this article will be shared on reasonable request to the corresponding author.

References

1. Lane DA, Skjøth F, Lip GYH, Larsen TB, Kotecha D. Temporal trends in incidence, prevalence, and mortality of atrial fibrillation in primary care. *J Am Heart Assoc* 2017; **6:** e005155.
2. Schnabel RB, Yin X, Gona P, Larson MG, Beiser AS, McManus DD, et al. 50-year trends in atrial fibrillation prevalence, incidence, risk factors, and mortality in the Framingham Heart Study: A cohort study. *Lancet* 2015; **386:** 154–162.
3. Kirchhof P, Benussi S, Kotecha D, Ahlsson A, Atar D, Casadei B, et al. 2016 ESC Guidelines for the management of atrial fibrillation developed in collaboration with EACTS. *Eur Heart J* 2016; **37:** 2893–2962.
4. Cresti A, García-Fernández MA, Sievert H, Mazzone P, Baratta P, Solari M, et al. Prevalence of extra-appendage thrombosis in non-valvular atrial fibrillation and atrial flutter in patients undergoing cardioversion: A large transoesophageal echo study. *EuroIntervention* 2019; **15:** e225–e230.
5. Healey JS, Crystal E, Lamy A, Teoh K, Semelhago L, Hohnloser SH, et al. Left Atrial Appendage Occlusion Study (LAAOS): Results of a randomized controlled pilot study of left atrial appendage occlusion during coronary bypass surgery in patients at risk for stroke. *Am Heart J* 2005; **150:** 288–293.
6. Kanderian AS, Gillinov AM, Pettersson GB, Blackstone E, Klein AL. Success of surgical left atrial appendage closure: Assessment by transesophageal echocardiography. *J Am Coll Cardiol* 2008; **52:** 924–929.
7. Lee R, Vassallo P, Kruse J, Malaisrie SC, Rigolin V, Andrei AC, et al. A randomized, prospective pilot comparison of 3 atrial appendage elimination techniques: Internal ligation, stapled excision, and surgical excision. *J Thorac Cardiovasc Surg* 2016; **152:** 1075–1080.
8. Caliskan E, Sahin A, Yilmaz M, Seifert B, Hinzpeter R, Alkadhi H, et al. Epicardial left atrial appendage AtriClip occlusion reduces the incidence of stroke in patients with atrial fibrillation undergoing cardiac surgery. *Europace* 2018; **20:** 127–132.
9. van Laar C, Verberkmoes NJ, van Es HW, Lewalter T, Dunnington G, Stark S, et al. Thoracoscopic left atrial appendage clipping: A Multicenter cohort analysis. *JACC Clin Electrophysiol* 2018; **4:** 893–901.
10. Sato S, Azami T, Fujisue J, Inoue K, Okada K. Usefulness of artificial pneumothorax during totally endoscopic off-pump left atrial closure and surgical ablation. *Ann Thorac Cardiovasc Surg* 2025; **31:** oa.24-00156.
11. Ohtsuka T, Nonaka T, Hisagi M, Ninomiya M, Masukawa A, Ota T. Thoracoscopic stapler-and-loop technique for left atrial appendage closure in nonvalvular atrial fibrillation: Mid-term outcomes in 201 patients. *Heart Rhythm* 2018; **15:** 1314–1320.
12. Nakahara S, Hori Y, Fukuda R, Sato H, Aoki H, Ishikawa T, et al. Chronic effect of hot balloon-based wide planar antral ablation on left atrial reverse remodeling in patients with persistent atrial fibrillation. *Circ Rep* 2023; **5:** 371–380.
13. Hosono K, Saji M, Wada R, Ohara H, Fujino T, Ikeda T. Pacing-assisted enhancement of left atrial appendage visualization during LAAC. *Cardiovasc Interv Ther* 2024; **39:** 221–222.
14. Ono K, Iwasaki Y, Akao M, Ikeda T, Ishii K, Inden Y, et al. JCS/JHRS 2020 Guideline on pharmacotherapy of cardiac arrhythmias. *J Arrhythm* 2021; **37:** 709–870.
15. Holmes DR, Reddy VY, Turi ZG, Doshi SK, Sievert H, Buchbinder M, et al. Percutaneous closure of the left atrial appendage versus warfarin therapy for prevention of stroke in patients with atrial fibrillation: A randomised non-inferiority trial. *Lancet* 2009; **374:** 534–542.
16. Ohtsuka T, Ninomiya M, Nonaka T, Hisagi M, Ota T, Mizutani T. Thoracoscopic stand-alone left atrial appendectomy for thromboembolism prevention in nonvalvular atrial fibrillation. *J Am Coll Cardiol* 2013; **62:** 103–107.

17. Holmes DR Jr, Kar S, Price MJ, Whisenant B, Sievert H, Doshi SK, et al. Prospective randomized evaluation of the Watchman left atrial appendage closure device in patients with atrial fibrillation versus long-term warfarin therapy: The PREVAIL trial. *J Am Coll Cardiol* 2014; **64:** 1–12.
18. Kar S. 24-month outcomes of PINNACLE FLX study with the WATCHMAN FLX™ left atrial appendage closure device. Presented at: Transcatheter Valve Therapy (TVT) Conference; July 21, 2021.
19. Nakashima M, Sakamoto A, Watanabe T, Kato Y, Yamada S, Nakamura K, et al. Comparative outcomes of WATCHMAN FLX versus 2.5 in Asian patients: insights from the OCEAN-LAAC Registry. *Circ J* 2024; **88:** 1187–1197.
20. Fukushima T, Fukunaga M, Isotani A, Nakamura M, Yamamoto K, Ishizu K, et al. Zero-contrast left atrial appendage closure in patients with chronic kidney disease. *Circ J* 2023; **88:** 170–174.
21. Ueno H, Imamura T, Tanaka S, Ushijima R, Fukuda N, Kinugawa K. Initial report of percutaneous left atrial appendage closure in hemodialysis patients with atrial fibrillation and high risk of bleeding in Japan. *Cardiovasc Interv Ther* 2023; **38:** 338–347.
22. Okada A, Taniguchi T, Shindo S, Nakao M, Yamashita K, Sakamoto Y, et al. Contrast-free WATCHMAN FLX implantation using intraprocedural imaging guidance. *Cardiovasc Interv Ther* 2024; **39:** 191–199.
23. Antaki T, Min J, Gorman J. Robotics-assisted epicardial left atrial appendage clip exclusion. *JTCVS Tech* 2021; **9:** 59–68.
24. Hasebe H, Yoshida K, Nogami A, Furuyashiki Y, Ieda M. Impact of interatrial epicardial connections on the dominant frequency of atrial fibrillation. *Circ J* 2023; **87:** 973–981.