JACC: ASIA VOL. 5, NO. 12, 2025
© 2025 THE AUTHORS. PUBLISHED BY ELSEVIER ON BEHALF OF THE AMERICAN COLLEGE OF CARDIOLOGY FOUNDATION. THIS IS AN OPEN ACCESS ARTICLE UNDER THE CC BY-NC-ND LICENSE (http://creativecommons.org/licenses/by-nc-nd/4.0/).

BRIEF REPORT

Isolated Thoracoscopic Left Atrial Appendage Occlusion Across 6 Centers

Early Outcomes and OAC Discontinuation

Taisuke Nakayama, MD, PhD,[a] Hiroshi Ito, MD, PhD,[b] Shunsuke Sato, MD,[c] Seimei Go, MD, PhD,[d] Gentaku Hama, MD,[e] Masakazu Aoki, MD,[f] Shinya Takahashi, MD, PhD[d]

Left atrial appendage (LAA) exclusion is an established strategy for stroke prevention in nonvalvular atrial fibrillation (AF), as most left atrial thrombi originate from the LAA.[1] Minimally invasive thoracoscopic left atrial appendage occlusion (LAAO) has gained traction in routine practice.[2] Contemporary electrophysiology surveys also reveal wide variability and growing interest in LAA management and postablation anticoagulation, underscoring the need for outcome-oriented surgical data.[3] However, multicenter evidence isolating the contribution of LAAO alone—without concomitant rhythm procedures—remains limited. We evaluated outcomes of isolated thoracoscopic LAAO within a multicenter Japanese registry.

Between March 2018 and December 2024, 567 AF patients underwent thoracoscopic LAAO across 6 institutions. We identified the LAAO-alone subgroup (n = 136; 24%), defined as patients without concomitant ablation; this subgroup constitutes the focus of this report. LAAO was performed thoracoscopically using stapling or epicardial clipping, with intraoperative transesophageal echocardiography (TEE) to confirm exclusion. Technical success required absence of residual stump or flow. The study was approved by institutional review boards (lead institutional review board: Chiba-Nishi General Hospital, No. TGE02505-025), and informed consent was obtained.

Analyses were prespecified. Continuous variables used nonparametric tests, and proportions used Pearson's chi-square/Fisher tests (2-sided $\alpha = 0.05$). Center-level global testing with multiplicity adjusted post hoc was applied when significant.

In the isolated thoracoscopic LAAO subgroup (n = 136) across 6 centers, procedural success was 100% with no operative deaths. Postoperative imaging (electrocardiogram-gated computed tomography and/or transthoracic echocardiography) was routinely performed per local protocols and confirmed consistently high rates of exclusion in the subgroup, consistent with the overall registry. Oral anticoagulation (OAC) withdrawal occurred immediately in 24%, within 1 month in 63%, and continued in 13% (**Figure 1**).

Between-center comparisons showed significant global differences in operation time and postoperative length of stay (LOS), with 1 center exhibiting longer times/LOS than others on post hoc testing. Early OAC discontinuation ≤30 days also showed some between-center differences. By contrast, imaging-confirmed closure was uniformly high, and no conversions occurred, indicating similar technical performance across institutions. These center-level variations likely reflect local protocols and team preferences rather than inherent limitations of the approach.

Sex-stratified analyses showed comparable early outcomes in women and men, without material

From the [a]Department of Cardiovascular Surgery, Chiba-Nishi General Hospital, Chiba, Japan; [b]Department of Cardiovascular Surgery, Saiseikai Shimonoseki General Hospital, Yamaguchi, Japan; [c]Department of Cardiovascular Surgery, Yodogawa Christian Hospital, Osaka, Japan; [d]Department of Cardiovascular Surgery, Hiroshima University Hospital, Hiroshima, Japan; [e]Department of Cardiovascular Surgery, Sapporo Cardiovascular Clinic, Sapporo Heart Center, Hokkaido, Japan; and the [f]Department of Cardiovascular Surgery, Matsumoto Kyouritsu Hospital, Nagano, Japan.

The authors attest they are in compliance with human studies committees and animal welfare regulations of the authors' institutions and Food and Drug Administration guidelines, including patient consent where appropriate. For more information, visit the Author Center.

Manuscript received August 26, 2025; revised manuscript received September 25, 2025, accepted September 26, 2025.

ISSN 2772-3747 https://doi.org/10.1016/j.jacasi.2025.09.009

FIGURE 1 Outcomes After Isolated Thoracoscopic LAAO

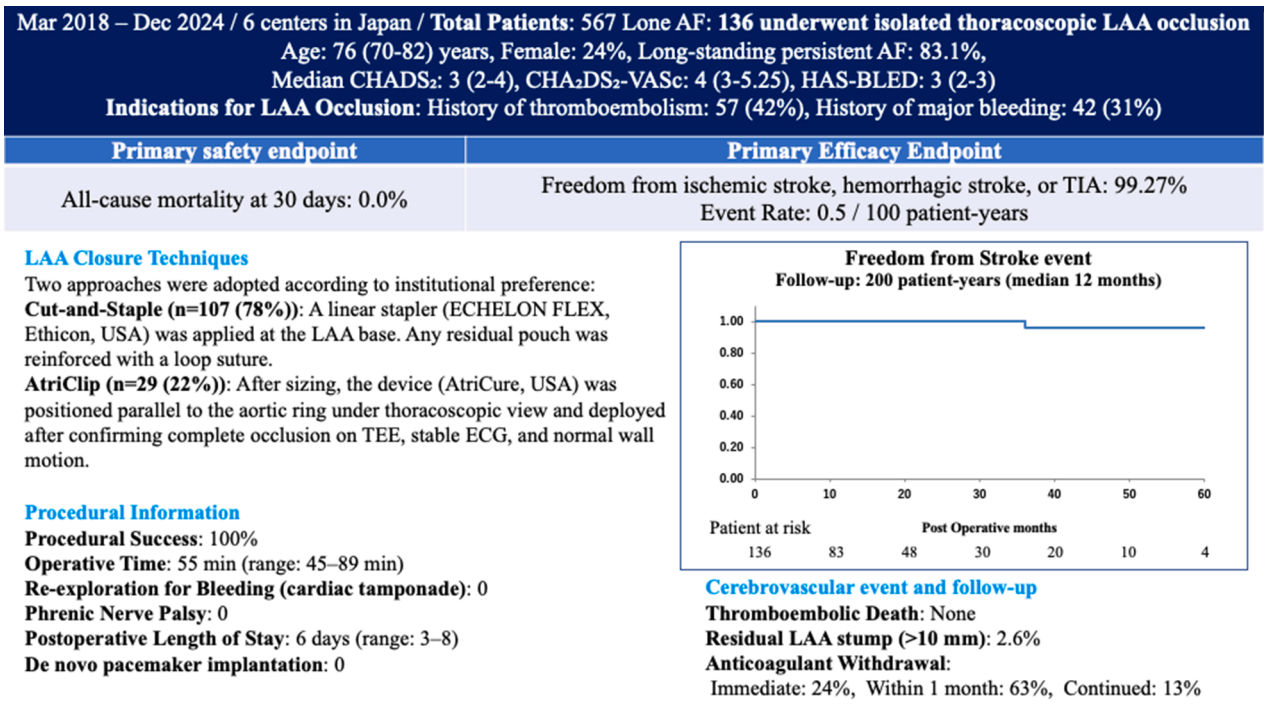

Multicenter cohort of 136 patients undergoing isolated thoracoscopic left atrial appendage (LAA) occlusion (LAAO) across 6 institutions (2018-2024). Two techniques were used (cut-and-staple 78%, clip 22%); procedural success was 100%. During a median 12-month follow-up (200 patient-years), cerebrovascular event-free survival was 99.27% (0.5/100 patient-years) with no thromboembolic deaths. The Kaplan-Meier curve includes 1 early postoperative ischemic stroke ($CHADS_2 = 5$) in an 84-year-old patient transferred before postoperative imaging. AF = atrial fibrillation; ECG = electrocardiogram; OAC = oral anticoagulation; TEE = transesophageal echocardiography; TIA = transient ischemic attack.

differences in technical success, imaging-confirmed closure, or early OAC management.

Overall, despite modest variations in workflow metrics (time and LOS) and OAC strategy, the procedure demonstrated high reproducibility and generalizability across centers, with consistent technical success and early safety/effectiveness in this isolated thoracoscopic LAAO cohort. During follow-up, no thromboembolic deaths occurred, and cerebrovascular events were rare. Cerebrovascular-event-free survival was 99.27% (0.5/100 patient-years) with no thromboembolic deaths (**Figure 1**); in the overall registry (875.8 patient-years), it was 99.47% (0.34/100 patient-years).

Our findings confirm prior reports of low cerebrovascular event rates and high closure success after thoracoscopic LAA exclusion,[2,4] while adding specificity by focusing on isolated thoracoscopic LAAO. Early outcomes were sex-independent, and center-level comparisons showed uniformly high technical performance and imaging-confirmed closure. The very low prevalence of residual stump/flow underscores the value of thoracoscopic visualization with real-time TEE. Recent series further align with these observations, including higher closure with epicardial clipping vs stapling[5] and a prospective AtriClip (AtriCure) cohort with excellent procedural performance.[6]

Early OAC withdrawal is a key clinical motivation in patients with bleeding concerns. In our practice, many patients discontinued OAC within 1 month after imaging verification (**Figure 1**). However, uniform evidence-based criteria are not yet established,[7] and real-world practice remains heterogeneous.[3] Against this backdrop, our data support a pragmatic pathway: imaging-confirmed exclusion plus rhythm surveillance to identify candidates for early OAC discontinuation after thoracoscopic LAAO. Prospective,

JACC: ASIA, VOL. 5, NO. 12, 2025
DECEMBER 2025:1566–1568

pragmatic pathways—integrating standardized postoperative imaging and rhythm surveillance—are needed to operationalize and validate this approach.

This study has limitations: retrospective design, nonstandardized imaging schedules and varying imaging availability across centers, modest subgroup sizes, and rare cerebrovascular events limiting statistical power for adjusted comparisons. Center differences in workflow metrics (operation time, LOS) likely reflect local protocols and team preferences rather than intrinsic limitations of the technique. These factors support an exploratory interpretation and call for validation in larger prospective cohorts.

In a 6-center cohort of isolated thoracoscopic LAAO, we observed consistent technical success, uniformly high imaging-confirmed closure, and sex-independent early outcomes, with many patients stopping OAC early after verified exclusion. Despite minor center-specific practice differences, the results indicate high reproducibility and generalizability of thoracoscopic LAAO as a stand-alone strategy for stroke prevention in nonvalvular AF, complementing prior single-center and multicenter experiences.[2,4-6]

DATA SHARING STATEMENT Data available upon request.

FUNDING SUPPORT AND AUTHOR DISCLOSURES

Dr Sato reports a non-financial relationship with Century Medical, Inc (Tokyo, Japan), outside the submitted work. All other authors report no relationships with industry relevant to this paper.

ADDRESS FOR CORRESPONDENCE: Dr Taisuke Nakayama, Department of Cardiovascular Surgery, Chiba-Nishi General Hospital, 107-1 Kanegasaku Matsudo-shi, Chiba-Ken 270-2251, Japan. E-mail: taisuke.nakayama0129@gmail.com.

REFERENCES

1. Blackshear JL, Odell JA. Appendage obliteration to reduce stroke in cardiac surgical patients with atrial fibrillation. *Ann Thorac Surg*. 1996;61:755–759.

2. Ohtsuka T, Ninomiya M, Nonaka T, et al. Thoracoscopic stand-alone left atrial appendectomy for nonvalvular atrial fibrillation. *J Am Coll Cardiol*. 2013;62:103–107.

3. Ellis CR, Alkhouli M, Holmes DR Jr, et al. Left atrial appendage closure: contemporary practice and perspectives among electrophysiologists and heart team members. *JACC Clin Electrophysiol*. 2017;3:869–874.

4. van Laar C, Verberkmoes NJ, van Es HW, et al. Thoracoscopic left atrial appendage clipping: short-term and midterm results of a multicenter cohort. *JACC Clin Electrophysiol*. 2018;4:893–901.

5. Lim SK, Kim JS, Park K, et al. Comparative outcomes of thoracoscopic left atrial appendage clipping versus stapled resection. *Ann Thorac Surg*. 2024;117(6):1230–1236.

6. Wang E, Zhou X, Liu J, et al. Thoracoscopic left atrial appendage occlusion with the AtriClip PRO2: results of 144 patients. *Heart Lung Circ*. 2024;33(8):1215–1220.

7. Kirchhof P, Benussi S, Kotecha D, et al. 2016 ESC guidelines for the management of atrial fibrillation. *Eur Heart J*. 2016;37:2893–2962.

KEY WORDS atrial fibrillation, left atrial appendage, minimally invasive cardiac surgery, stroke, totally thoracoscopic procedure