Interdisciplinary CardioVascular and Thoracic Surgery 2025, 40(10), ivaf172
https://doi.org/10.1093/icvts/ivaf172 Advance Access publication 24 October 2025

ORIGINAL ARTICLE

Cite this article as: Nakayama T, Nakamura Y, Shukuya A, Hashimoto S, Higuma Y, Niitsuma K *et al*. Speech Bubble Sign—Insights Regarding Incomplete Left Atrial Appendage Closure via Electrocardiography-Synchronized Computed Tomography in Robotic Surgery Cases. Interdiscip CardioVasc Thorac Surg 2025; doi:10.1093/icvts/ivaf172.

Speech Bubble Sign—Insights Regarding Incomplete Left Atrial Appendage Closure via Electrocardiography-Synchronized Computed Tomography in Robotic Surgery Cases

Taisuke Nakayama[1]; Yoshitsugu Nakamura*[,1]; Atsushi Shukuya[2]; Shinya Hashimoto[2]; Yuka Higuma[1]; Kusumi Niitsuma[1]; Masaki Ushijima[1]; Yuto Yasumoto[1]; Miho Kuroda[1]; Kosuke Nakamae[1]; Akihiro Higashino[1]; Yujiro Hayashi[1]; Ryo Tsuruta[1]; Yujiro Ito[1]

[1]Department of Cardiovascular Surgery, Chiba-Nishi General Hospital, Chiba 270-2251, Japan
[2]Department of Radiology, Chiba Nishi General Hospital, Chiba 270-2251, Japan

*Corresponding author. Department of Cardiovascular Surgery, Chiba-Nishi General Hospital, 107-1 Kanegasaku Matsudo-shi, Chiba-Ken, Chiba 270-2251, Japan (ystgnkmr@gmail.com)

Received: March 7, 2025; Revised: April 16, 2025; Accepted: July 11, 2025

Graphical abstract

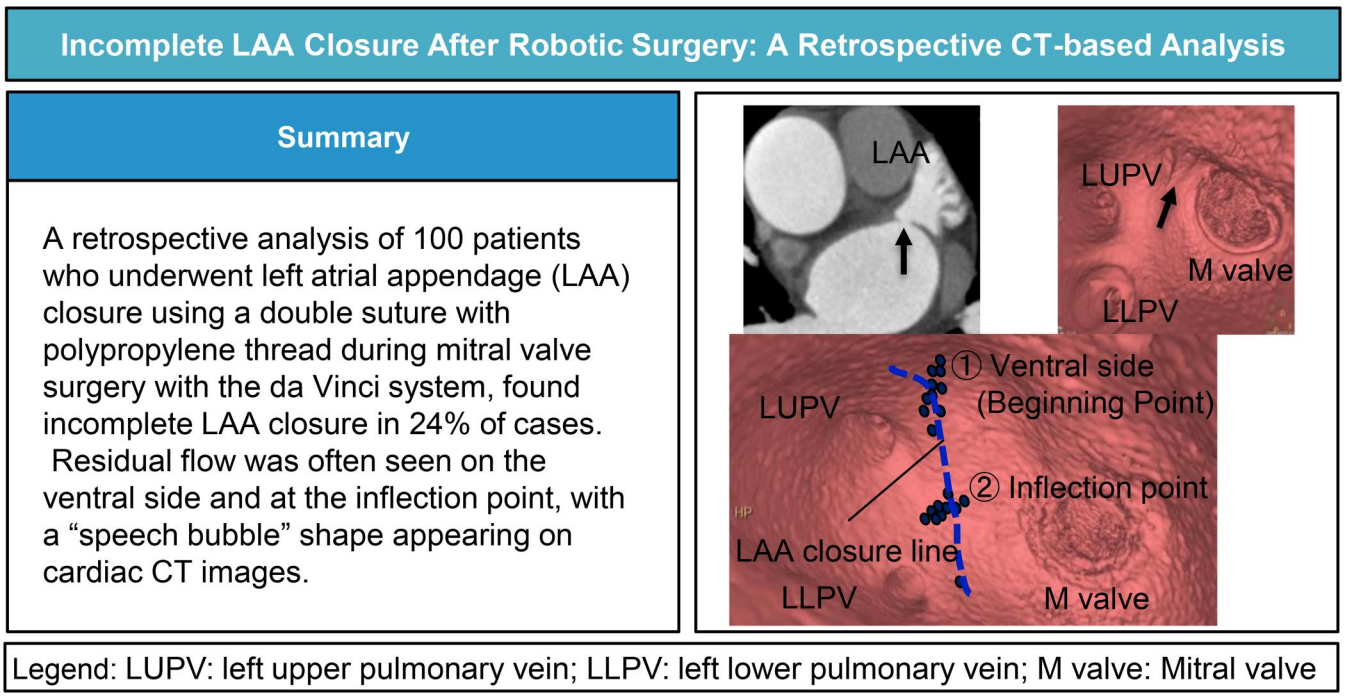

Abstract

Objectives: In atrial fibrillation (AF), surgical management of the left atrial appendage (LAA) is crucial to prevent stroke. However, incomplete closure poses a residual embolic risk.

All authors listed above have contributed to the manuscript and satisfy the ICMJE criteria for authorship.

© The Author(s) 2025. Published by Oxford University Press on behalf of the European Association for Cardio-Thoracic Surgery.
This is an Open Access article distributed under the terms of the Creative Commons Attribution-NonCommercial License (https://creativecommons.org/licenses/by-nc/4.0/), which permits non-commercial re-use, distribution, and reproduction in any medium, provided the original work is properly cited. For commercial re-use, please contact reprints@oup.com for reprints and translation rights for reprints. All other permissions can be obtained through our RightsLink service via the Permissions link on the article page on our site—for further information please contact journals.permissions@oup.com.

Downloaded from academic.oup.com/icvts/article/40/10/ivaf172/8300855 by guest on 02 October 2026

Methods: We retrospectively analysed patients who underwent LAA closure using a continuous polypropylene suture technique during mitral valve surgery with the da Vinci system. Closure completeness was assessed via electrocardiogram-gated computed tomography (CT), and 3D imaging was used to localize incomplete sites.

Results: Of 125 patients, 100 underwent postoperative CT. Complete closure (cLAA) was achieved in 76%, while 24% had incomplete closure (iLAA), typically at the mitral valve junction or suture start. These showed a characteristic "speech bubble" appearance. iLAA was associated with tricuspid valve repair and low V1 f-wave amplitude. Stroke rates were similar between groups over 24 months.

Conclusions: Incomplete LAA closure occurred in 24% of cases despite direct visualization using robotics. Anatomical factors likely contribute more than technique alone. For high-risk patients with long-standing AF, techniques such as lumen crushing or external clips may enhance closure success. Further refinements are needed to improve the reliability of internal LAA closure methods.

Keywords: atrial fibrillation; left atrial appendage; minimally invasive cardiac surgery; stroke; robotic left atrial appendage closure; electrocardiography-synchronized CT.

INTRODUCTION

Atrial fibrillation (AF) significantly increases the risk of intracardiac thromboembolism, with the left atrial appendage (LAA) being the source of clots in up to 90% of non-rheumatic AF cases.[1,2] Current guidelines recommend LAA closure in AF patients undergoing mitral valve or maze surgery.[3] The LAAOS study confirmed its safety and efficacy in reducing cardiogenic stroke.[4] Robotic surgery, particularly with the da Vinci system, has improved precision and visualization in minimally invasive procedures. During mitral valve surgery, the system allows for simultaneous LAA closure from within the left atrium (LA), enhancing efficiency. Prior studies have reported high rates of incomplete closure with suture ligation, leading to increased thromboembolic risk,[5–8] though these were based on direct vision approaches. No studies have focused specifically on robotic LAA closure. Enhanced visualization with robotics may improve closure success through precise suturing. Although some studies addressed lumen closure,[9,10] few analyse anatomical sites prone to reopening.

This study investigates anatomical sites of LAA reopening using ECG-gated CT, based on 78 months of robotic LAA closure experience since July 2018. It aims to identify technical principles that improve outcomes with the double continuous-suture technique.

METHODS

This retrospective study was approved by the institutional ethics committee (TGE02656-025), with informed consent waived. LAA closure was performed during mitral valve surgery using the da Vinci system in patients with paroxysmal or persistent AF. This study did not involve the collection or long-term storage of biological materials or data for future unspecified use; therefore, the WMA Declaration of Taipei was not applicable. All procedures were conducted by the same surgeon (Y.N.) and assistant (M.K.). Closure outcomes were assessed by ECG-gated cardiac CT.

Potential causes of incomplete closure were examined from patient, anatomical, and technical perspectives. We also evaluated whether these factors contributed to embolic or bleeding complications. Follow-up was via outpatient visits or phone interviews at 1, 3, 6, 12, 18, and 24 months postoperatively, then annually. These methods helped minimize verification bias.

Stroke was defined as a neurological deficit lasting over 24 hours, confirmed by neurologist and imaging where possible. Postoperative stroke required both clinical and CT or MRI confirmation. Major bleeding was defined per ISTH criteria[11]: fatal bleeding, critical organ bleeding (eg, intracranial, pericardial), or bleeding causing ≥2.0 g/dl haemoglobin drop or ≥2-unit transfusion.

Surgical technique

Under general anaesthesia and one-lung ventilation in a half-supine position, a 4-cm incision between the right fourth and fifth ribs served as the working port. Femoral arterio-venous cannulation established cardiopulmonary bypass as previously described.[12] Ports were inserted, the pericardium opened and retracted. A cardioplegia cannula was inserted into the ascending aorta and clamped via the transverse sinus. The robot was docked and thoracoscopic procedures performed. Myocardial arrest was induced per standard protocol.[13] The LA was incised using robotic scissors, and the mitral valve exposed with a retractor.

LAA closure used a continuous double polypropylene suture, starting ventrally. From the 65th case, felt-reinforced nodal sutures were added; from the 83rd case, horizontal mattress sutures were combined with over-and-over sutures. Extra nodal sutures were placed as needed.

Computed tomography

Preoperative ECG-gated CT assessed LA and LAA volume, size, morphology, and proximity to coronary arteries. Measurements were taken using Philips IntelliSpace Portal (slice thickness 0.8 mm, increment 0.4 mm, and 75% cardiac phase). LAA morphology was classified as cactus, chicken wing, windsock, or cauliflower.[14]

Three to 6 months postoperatively, contrast-enhanced CT was performed unless contraindicated. Early and delayed phases were analysed using ECG synchronization. Incomplete closure (iLAA) was identified by delayed-phase contrast in the LAA lumen. Complete closure (cLAA) showed no residual contrast. For iLAA, 3D LA images were reconstructed to locate communication sites relative to the mitral valve.

Downloaded from academic.oup.com/icvts/article/40/10/ivaf172/8300855 by guest on 02 October 2026

Postoperative anticoagulant management

For the first 3 postoperative months, all patients received direct oral anticoagulants (DOAC) or warfarin (vitamin K antagonist; VKA) regardless of rhythm. VKAs were used after valve replacement, and DOACs after valve repair. If sinus rhythm was confirmed on ECG at 3 months, anticoagulation was discontinued. Contrast-enhanced CT was performed between 3 and 6 months to assess left atrial flow; however, the presence or absence of residual LAA flow was not a determining factor for continuing anticoagulation. Thereafter, therapy was individualized, except in patients with cardiac dysfunction or valve replacement, where it was routinely continued. In patients with high bleeding risk (eg, prior GI bleeding), anticoagulation was discontinued even with persistent AF.

Statistical analysis

Basic statistics were calculated for baseline demographic and clinical parameters. Continuous variables are presented as medians with interquartile ranges, expressed as the 25th and 75th percentiles (p25; p75). Categorical variables are expressed as frequencies and percentages (%). Time-to-event data, such as stroke incidence, were analysed using Kaplan-Meier survival curves. To explore factors associated with iLAA, univariate logistic regression analysis was performed. Variables deemed clinically relevant or demonstrating potential associations were subsequently included in a multivariate logistic regression model to identify independent predictors. A 2-sided *P*-value of $<.05$ was considered statistically significant. All statistical analyses were performed using Excel statistical software (Ekuseru-Toukei; Social Survey Research Information Co., Tokyo, Japan).

RESULTS

Between July 2018 and December 2023, a total of 125 patients with paroxysmal or persistent AF associated with mitral valve disease underwent LAA closure during mitral valve surgery using the da Vinci surgical system. No adverse events, including bleeding, arrhythmia, myocardial ischaemia, cardiac or noncardiac injury, stroke, or death, were reported. Notably, no left circumflex artery injury occurred during LAA closure.

Among these patients, 100 were eligible for postoperative evaluation using electrocardiogram-synchronized computed tomography. The 25 excluded patients included 12 with renal dysfunction and 7 with contraindications to contrast media, such as asthma or a contrast media allergy. Additionally, 6 patients were ineligible for CT imaging due to difficulties visiting the hospital as outpatients, such as living too far away. Patient demographic data are summarized in **Table 1**. The median age was 73 years, 55% were female, and the median body surface area was 1.51 m^2. Twelve patients had chronic renal failure, though none required dialysis. Paroxysmal AF was present in 40%, while 60% had long-standing persistent AF. The $CHADS_2$ and CHA_2DS_2-VASc scores were 2 and 4, respectively. Cardiac function was generally preserved, with an median left ventricular ejection fraction of 67.2% and a left atrial diameter of 47.6 mm. Most patients had moderate to severe mitral regurgitation, and 51% had moderate to severe tricuspid regurgitation.

Postoperative computed tomography angiography in the evaluated patients revealed complete LAA closure in 76 (76%) cases and incomplete closure in 24 (24%) cases. In incomplete closure cases, a small, speech balloon-like opening was observed on imaging (**Figure 1**).

Surgery-related factors are summarized in **Table 2**. Among patients with incomplete closure, tricuspid valve plasty was performed in several cases, whereas maze procedures were less commonly documented. There were no early deaths, postoperative haemorrhages requiring reoperation, or in-hospital strokes. During follow-up, residual or recurrent AF occurred in 35% of all patients. This was observed in 14 patients (58%) within the iLAA group. Postoperative medications, including DOAC and VKA, were comparable across groups. The follow-up period exceeded 20 months in both groups.

Postoperative CT evaluations

The median time from surgery to CT evaluation was 4 months (interquartile range, 3-13 months). A CT scan from the cLAA group (**Figure 2**) showed complete LAA closure, with reduced volume and a smooth, spherical LA. EP planning images revealed a regular LAA lumen and a clean intima (refer to **Video 1** for procedural details).

In contrast, CT scans from the iLAA group (**Figure 3-1** and **3-2**) revealed blood flow entering the LAA through a small pore, with unchanged LAA volume. EP planning images identified openings, most commonly at the ceiling side where closure begins (50%, **Figure 3-1**) and at the left inflection point near the mitral valve and left superior pulmonary vein (45%, **Figure 3-2**). **Videos 2** and **3** provide procedural details. In one iLAA case, the LAA was fully reopened by cutting the suture, while in 3 cases, the openings were challenging to locate (**Table 1**, **Figure 4**).

Twenty-four iLAA patients underwent additional follow-up CT. The second follow-ups, at an mean of 16.8 ± 10 months (18 patients), and third follow-ups, at 26.6 ± 4.7 months (4 patients), showed that only one patient achieved complete LAA closure by 18 months. In the remaining 23 patients, persistent blood flow indicated incomplete closure throughout the follow-up period.

Postoperative late events

The follow-up period ranged from 3 to 66 months, with a median of 24 months (IQR: 15-38 months). Median follow-up was 31 months in the cLAA group and 21.5 months in the iLAA group. This difference is presented descriptively, as the study was not powered to assess statistical differences in follow-up duration. Anticoagulant therapy (DOAC or VKA) was discontinued in 52% of patients based on AF status and patient consultation. In the cLAA group, 30 patients continued DOAC therapy, and 5 remained on VKA. Among the 24 iLAA cases, 10 patients achieved sinus rhythm, and despite incomplete closure, the embolic risk was deemed low due to the speech bubble-like morphology. After thorough explanation, anticoagulation was discontinued. The remaining 14 patients had persistent AF and were generally indicated for anticoagulation;

Downloaded from academic.oup.com/icvts/article/40/10/ivaf172/8300855 by guest on 02 October 2026

Table 1. Baseline Patient Characteristics Stratified by LAA Closure Outcome

Variables	All patients (n = 100)	cLAA (n = 76)	iLAA (n = 24)
Age, years	73 (66.5-78.5)	71(65-78)	75 (71-79)
Female	55 (55%)	44 (58%)	11 (46%)
Body surface area, m^2	1.51 (1.37-1.65)	1.53 (1.37-1.7)	1.59 (1.45-1.67)
Hypertension	55 (55%)	39 (51%)	16 (67%)
Diabetes mellitus	19 (19%)	13 (17%)	6 (25%)
Chronic obstructive pulmonary disease	8 (8%)	9 (12%)	0 (0%)
Chronic kidney disease	12 (12%)	10 (13%)	2 (8.3%)
Dialysis	0 (0%)	0 (0%)	0 (0%)
Congestive heart failure	42 (42%)	30 (39%)	12 (50%)
Cardiovascular implantable electronic device	2 (2%)	2 (2.6%)	0 (0%)
SSE (ischaemic stroke/systemic embolization)	24 (24%)	20 (26%)	4 (17%)
Long persistent AF	60 (60%)	44 (58%)	16 (67%)
Paroxysmal AF	40 (40%)	32 (42%)	8 (33%)
Low voltage f-wave (<0.2 mV)	12 (12%)	4 (5.3%)	8 (33%)
CHADS2 score	2 (1-3)	2 (1-3)	2 (1-3)
≥2	61 (61%)	44 (58%)	17 (71%)
CHA2DS2-VASc score	4 (2-5)	3 (2-5)	4 (2.25-5)
≥3	69 (69%)	51 (67%)	18 (75%)
Left ventricular ejection fraction, %	67.2 (61.3-73.4)	67.8 (62-73.1)	66 (59.6-74.5)
Left atrial diameter, mm	47.6 (42.3-59.6)	47.4 (41.9-57.7)	50.6 (43-66.7)
Mitral valve regurgitation (moderate-severe or severe)	98 (98%)	75 (98.7%)	23 (95.8%)
Tricuspid valve regurgitation (≥moderate)	51 (51%)	39 (51.3%)	12 (50%)
LAA morphology			
Cactus	16 (16%)	11 (15%)	5 (21%)
Chicken wing	52 (52%)	41 (54%)	11 (46%)
Windsock	8 (8%)	7 (9%)	1 (4%)
Cauliflower	24 (24%)	17 (22%)	7 (29%)
LAA dimension			
Width, mm	44.1 (37.7-49.1)	44.4 (38.1-49.2)	43 (33.5-47.8)
Inlet length, mm	28.6 (22.8-33.2)	28.4 (22.9-32)	32.3 (21.2-34.7)
Volume, cc	15.1 (10-20.7)	15 (10.3-20.2)	17.5 (8.7-25)
LAA closed technique			
Over and over ×2	82 (82%)	60 (69%)	22 (92%)
Over and over + Mattress	17 (17%)	15 (19%)	2 (8.3%)
Reopening pattern			
Complete opening			1 (4%)
Indeterminate			3 (12%)
Speech bubble			20 (84%)
Speech bubble type traffic area			
Beginning point of closure			10 (50%)
Inflection point of closure			9 (45%)
Terminal point of closure			1 (5%)

$CHADS_2$ and CHA_2DS_2-VASc scores were defined according to standard criteria. Values are presented as n (%) for categorical variables and as median (25th-75th percentile) for continuous variables. AF, atrial fibrillation; LAA, left atrial appendage; cLAA, complete closure; iLAA, incomplete closure; SSE, stroke/systemic embolization.

12 continued therapy, while 2 discontinued due to patient-specific factors, such as prior gastrointestinal bleeding, following careful evaluation.

Two deaths from pneumonia occurred at 4 and 38 months, with no cardiac, embolism, or bleeding-related deaths. Two patients experienced cerebral infarction: one atherosclerotic stroke in the cLAA group at 5 months (postoperative AF, DOAC continued) and a lacunar infarction in the iLAA group at 19 months (postoperative sinus rhythm, DOAC continued). One haemorrhagic complication, a spinal subdural haematoma, occurred at 29 months in the cLAA group (postoperative sinus rhythm, DOAC continued but later discontinued). Kaplan-Meier curves for stroke and bleeding complications are shown in **Figure 5**.

DISCUSSION

The LAAOS III trial[4] demonstrated that LAA closure performed during cardiac surgery effectively prevents stroke; however, it did not explicitly discuss the closure methods or the quality of closure. Notably, the trial reported that double-layer linear closure from the endocardial side was utilized in 13.8% of patients, highlighting the importance of reliable intraoperative assessment through transoesophageal echocardiography (TEE). However, electrocardiogram-gated cardiac CT was not employed in that study to evaluate closure integrity. Our study is the first to systematically assess the indications and limitations of LAA closure using the da Vinci surgical system, and specifically to employ electrocardiogram-gated cardiac CT imaging for postoperative evaluation of closure effectiveness.

Downloaded from academic.oup.com/icvts/article/40/10/ivaf172/8300855 by guest on 02 October 2026

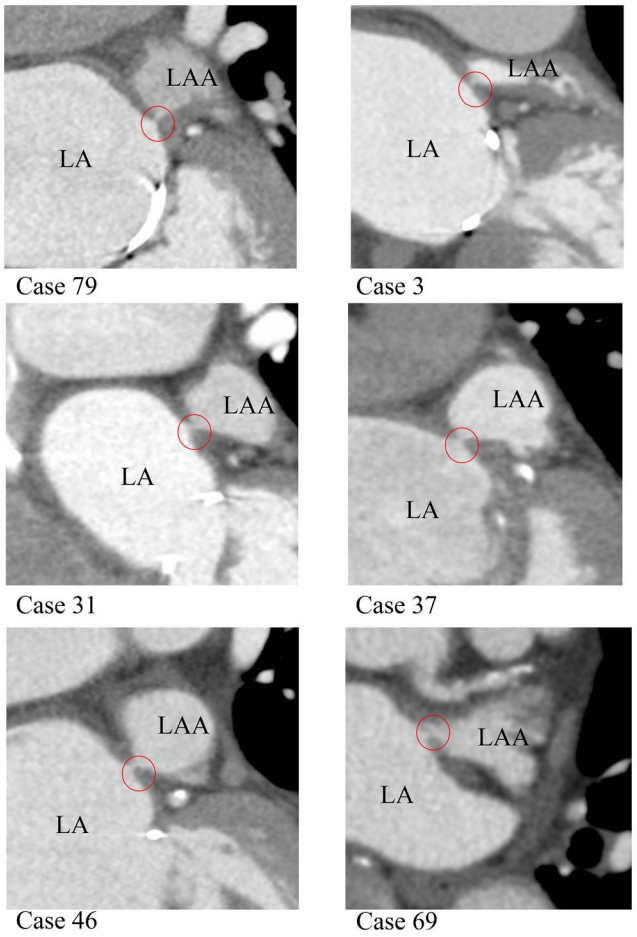

Figure 1. Incomplete LAA Closure with Characteristic "Speech Bubble" Appearance. Circled region indicates residual communication between the LA and LAA

Aryana et al[15] analysed 72 patients who underwent simultaneous mitral valve and maze surgery with suture closure of the LAA from the cardiac lumen, using CT for evaluation. They found cLAA in 64% and iLAA in 24%, similar to this study. SSE risk correlated with the degree of LAA closure. At 44 ± 19 months post-surgery, recurrent AF rates were similar, but SSE occurred in 2% of cLAA and 24% of iLAA patients. Notably, all patients with SSE had recurrent AF and were not on DOAC. The annualized SSE risk was 1.9% overall, 6.5% for iLAA patients, and 14.4% for iLAA patients not on DOAC. Univariable and multivariable analyses identified iLAA as the sole independent SSE predictor, highlighting the need for high-quality LAA closure. Branzoli et al[16] studied patients undergoing LAA closure before robotic mitral valve repair, similar to this study. Using a 2-layer running 4-0 polytetrafluoroethylene suture, they evaluated results with transoesophageal echocardiography, achieving successful ligation in 87.7% of cases. Of these, 9.6% had small jet flow into the LAA but no residual stumps, while 2.7% had undetermined flow. In our cohort, intraoperative TEE revealed undetermined LAA flow in some patients, but postoperative TEE was not performed. In some cases, contrast-enhanced CT detected blood flow even when TEE did not, warranting further investigation.

Table 2. Procedural Characteristics and Outcomes

Variables	cLAA (n = 76)	iLAA (n = 24)
Operative		
Mitral valve repair	71 (93%)	19 (79%)
Mitral valve replacement	5 (6.6%)	5 (21%)
Tricuspid valve annuloplasty	26 (34%)	18 (75%)
Maze surgery	43 (57%)	7 (29%)
Left atrial plication	3 (4%)	1 (4%)
Mitral valve, rigid, or semi-rigid ring	28 (39%)	8 (42%)
Mitral valve ring, flexible	42 (59%)	8 (42%)
Ring or prosthetic valve size (mm)	28 (28-30)	28 (28-30)
Postoperative		
Long-term postoperative AF	21 (28%)	14 (58%)
Postoperative pharmacologic therapy		
DOAC	42 (55%)	16 (67%)
VKA	33 (43%)	8 (33%)
Antiplatelet drug	3 (4%)	0 (0%)
Antiarrhythmic drug	10 (13%)	4 (17%)
Beta blocker	49 (64%)	9 (38%)
Statin	12 (16%)	4 (17%)
ACE-I/ARB	17 (22%)	9 (38%)
Diuretic drug	70 (92%)	23 (96%)
Follow-up, months	31 (13-46)	21.5 (12-32)

Values are presented as n (%) for categorical variables and as median (25th-75th percentile) for continuous variables. Values are presented descriptively without statistical comparison between groups. DOAC, direct oral anticoagulant; VKA, vitamin K antagonist.

There are 2 primary approaches to LAA closure: the medial approach, as used in the present cases, and the lateral approach. Traditional external methods involved excisional suture closure and stapling,[8] but recent outcomes with epicardial clips have been favourable. Younju et al[17] analysed 108 AF patients who underwent epicardial LAA clipping with or without simultaneous cardiac surgery using a minimally invasive approach. They reported a procedural success rate of 92.2%, with postoperative CT confirming complete LAA elimination without residual stumps or device-related complications such as bleeding, migration, or reoperation. The lateral approach is generally considered more reliable for securely closing the LAA from its base. Antaki et al[18] also reported success with a lateral approach using the DaVinci system, achieving effective closure with a clip. However, this approach is technically demanding and adds complexity when combined with right-sided mitral valve surgery, requiring additional ports. Its ability to consistently identify the LAA's origin compared to a left-sided approach remains unclear. Kuzmin et al[19] highlighted a risk with clip placement: if the clip is too close to the LAA base, it may obstruct or damage the LCx. Preoperative CT is crucial to assess the spatial relationship between the LAA and LCx. Despite their advantages, the high cost of clips remains a significant concern.

Increased thromboembolic risk associated with incomplete LAA closure after surgical ligation has been reported,[5] but definitions vary across studies. These include "residual anatomic structure between the mitral valve base and the left superior pulmonary vein,"[5,6] "residual stump of 1.0 cm or more," and "persistent flow in the LAA after surgical exclusion."[7] In line with Healey et al, we define incomplete LAA closure as persistent flow into the LAA. Anatomical factors significantly contribute to

Downloaded from academic.oup.com/icvts/article/40/10/ivaf172/8300855 by guest on 02 October 2026

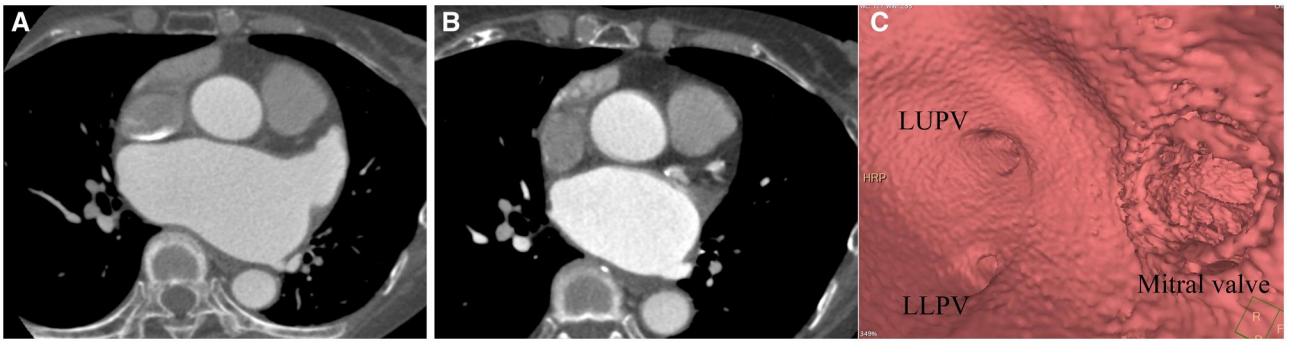

Figure 2. (A) Preoperative ECG-gated CT showing LAA presence. (B and C) Postoperative 2D and EP planning CTs from case 44 show successful closure with no flow and smooth LAA surface. LUPV, left upper pulmonary vein; LLPV, left lower pulmonary vein

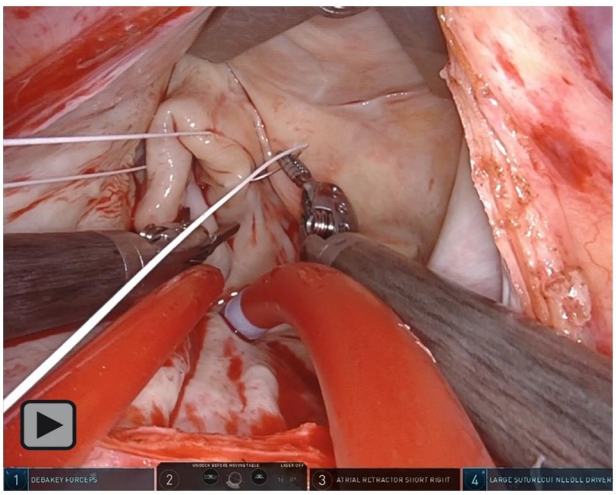

Video 1. Da Vinci-assisted LAA closure procedure demonstrating complete closure (Case 44)

incomplete LAA closure. The LAA's unique embryonic origin and trabeculated walls, resembling ventricles due to pectinate muscles,[20,21] contrast with the smooth-walled atrium. Its complex anatomy, located in the left atrioventricular sulcus near the left circumflex coronary artery and great cardiac vein,[22,23] impacts closure success. An inflection point along the LAA closure line often becomes prone to recanalization, especially under resumed blood flow after cardiac arrest. Increased left atrial blood volume also raises the likelihood of reopening. Closing only the LAA entrance may fail due to its stretched anatomy. In our study, incomplete closures showed "speech bubble" formations, likely due to this mechanism. Furthermore, the risk of incomplete closure tended to be higher in patients with AF who exhibited low-voltage f-waves, cases in which completion of the maze procedure was not feasible, and cases requiring concomitant tricuspid valve surgery. Rather than being attributable to surgical technique, these findings likely reflect advanced myocardial remodelling in AF, which leads to anatomical changes that predispose the LAA to form residual spaces or pouches after closure. This interpretation is supported by our multivariate analysis (**Table S1**), which identified tricuspid valve annuloplasty and low-voltage f-waves in lead V1 as independent predictors of incomplete LAA closure. These variables likely serve as surrogate markers of atrial remodelling, rather than direct mechanical contributors to closure failure. To address these anatomical challenges, we are exploring a technique that involves collapsing and sealing the LAA lumen rather than simply suturing its entrance. This approach is particularly crucial for achieving complete closure in high-risk patients. We have applied this lumen collapse technique in 10 cases, successfully closing the LAA without creating pouch-like formations. However, this method carries an increased risk of bleeding, necessitating caution, especially in cases with strong adhesions.

It goes without saying that the primary goal of closing the LAA is to prevent cardiogenic stroke. However, another major purpose may be to discontinue anticoagulant medication to address the risk of bleeding complications. While there is no clear evidence that closing the LAA leads to discontinuation of anticoagulant therapy, it has been reported that more than 90% of thrombogenic sites in AF cases occur in the LAA,[24] and thus, it may help to stop anticoagulation in those with a bleeding risk. A report by Antaki et al[18] noted that nearly all patients discontinued DOAC after LAA closure with use of a clip, except for one with a CHA2DS2-VASc score of 9. Additionally, post-clip bleeding was noted in only 2 of 108 gastrointestinal haemorrhage patients, while no transient ischaemic attack or stroke occurrence was noted in the 25 patients who completed the 12-month follow-up examination. That report noted that lack of significant haemorrhage or stroke after LAA closure with use of a clip lends credibility to the concept of epicardial clip exclusion for the LAA. As for the present cases, anticoagulants could be discontinued in 52 patients and the only bleeding complication noted was a spinal subdural Haemorrhage in one in whom DOAC was continued. There are no clear criteria for discontinuing anticoagulant administration. Should the decision be based on maintenance of sinus rhythm, complete closure of the LAA, or both? Further accumulation of evidence will be needed to address these issues.

Study limitations

This retrospective, single-centre study has several limitations, including selection bias and lack of a control group. CT imaging was not performed in patients with renal dysfunction or contrast allergy, which may limit generalizability. Image quality may have been affected by suboptimal heart rate control. Additionally, outcomes reflect procedures by a single surgical team,

Downloaded from academic.oup.com/icvts/article/40/10/ivaf172/8300855 by guest on 02 October 2026

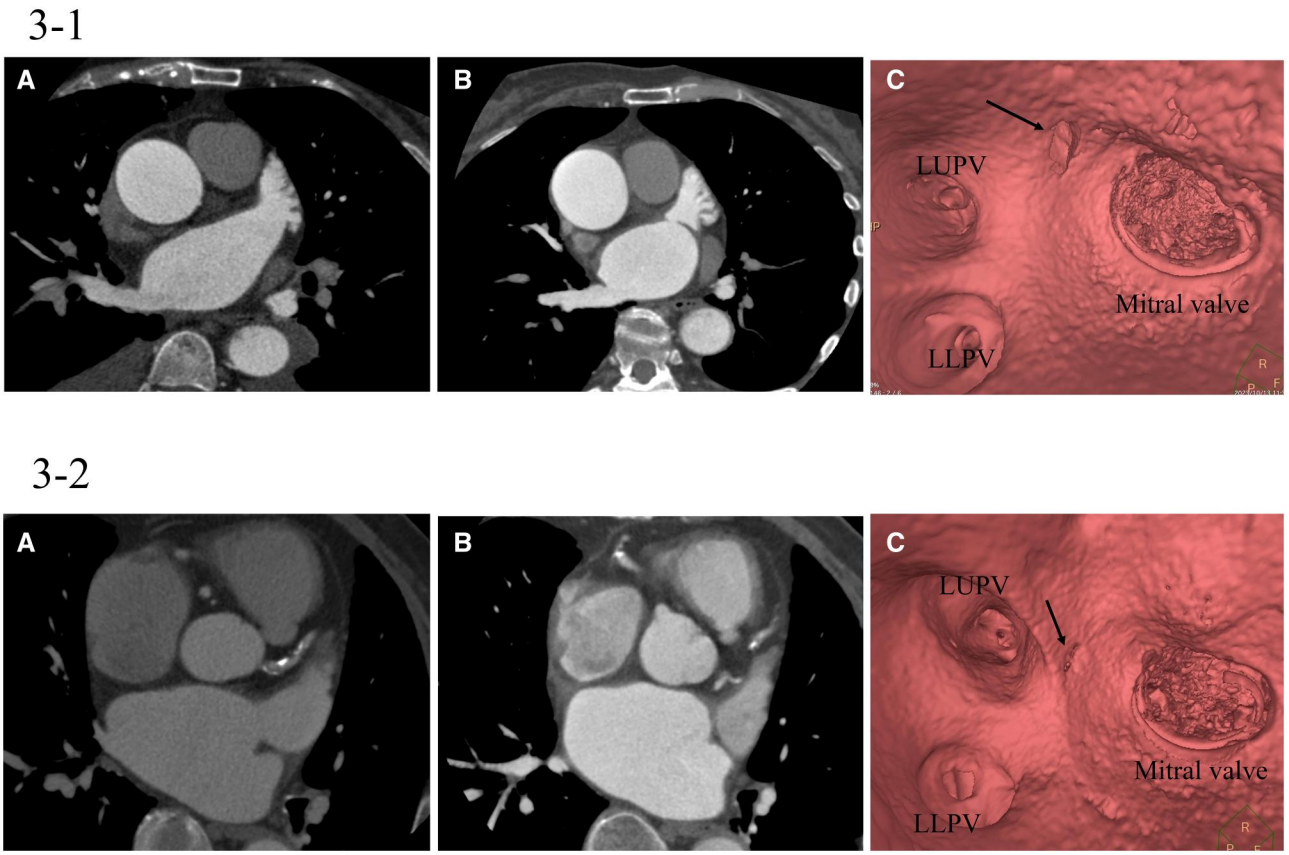

Figure 3. (A) Preoperative ECG-gated CT. (B and C) Postoperative 2D and EP CTs. (3-1) Case 52: failed closure, communication at suture start. (3-2) Case 85: failed closure, communication at suture inflection. Arrows indicate leakage sites. LUPV, left upper pulmonary vein; LLPV, left lower pulmonary vein

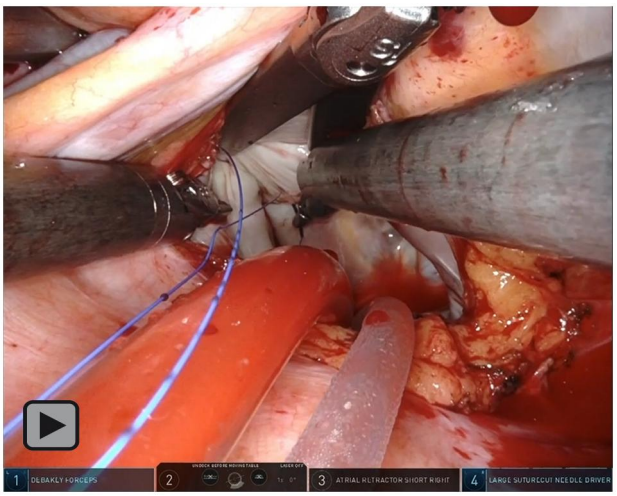

Video 2. Da Vinci-assisted LAA closure showing incomplete closure at the suture start (Case 52)

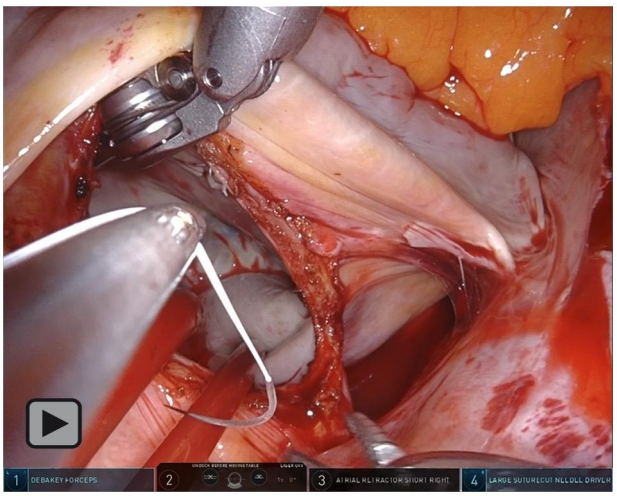

Video 3. Da Vinci-assisted LAA closure showing incomplete closure at the suture inflection point (Case 85)

potentially limiting reproducibility. Despite these limitations, the findings offer useful insights and may inform future research.

CONCLUSIONS

This study highlights the limitations of current methods for closing the LAA from the inside. Even with direct visual closure using the Da Vinci system, residual flow was observed on the ventral side, where closure begins, and at the inflection point of the closure line, suggesting room for improvement with future advancements. In patients with long-term AF, those not undergoing maze surgery, or those with tricuspid disease, the risk of residual blood flow in the LAA is high. For these high-risk patients, alternative techniques, such as collapsing the

Downloaded from academic.oup.com/icvts/article/40/10/ivaf172/8300855 by guest on 02 October 2026

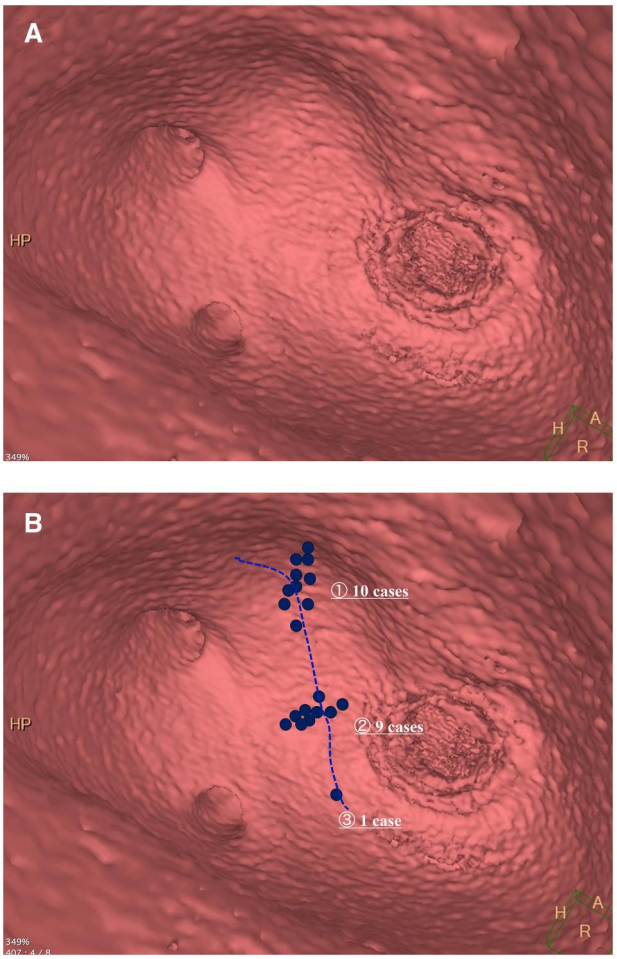

Figure 4. LAA Orifice Location Patterns. (A) Case with no identifiable orifice. (B) Summary: Suture start; Inflection point; and Terminal end

appendage lumen for complete occlusion or using external clips, may be crucial to ensure full closure.

AUTHOR CONTRIBUTIONS

Taisuke Nakayama: Data curation; Formal analysis; Investigation; Writing—original draft. Yoshitsugu Nakamura: Conceptualization; Investigation; Supervision. Atsushi Shukuya: Formal analysis. Shinya Hashimoto: Formal analysis. Yuka Higuma: Data curation. Kusumi Niitsuma: Formal analysis. Masaki Ushijima: Formal analysis. Yuto Yasumoto: Investigation. Miho Kuroda: Investigation. Kosuke Nakamae: Investigation. Akihiro Higashino: Data curation. Yujiro Hayashi: Data curation. Ryo Tsuruta: Data curation. Yujiro Ito: Formal analysis.

SUPPLEMENTARY MATERIAL

Supplementary material is available at *ICVTS* online.

FUNDING

Not applicable.

CONFLICTS OF INTEREST

None declared.

DATA AVAILABILITY

The data underlying this article will be shared on reasonable request to the corresponding author.

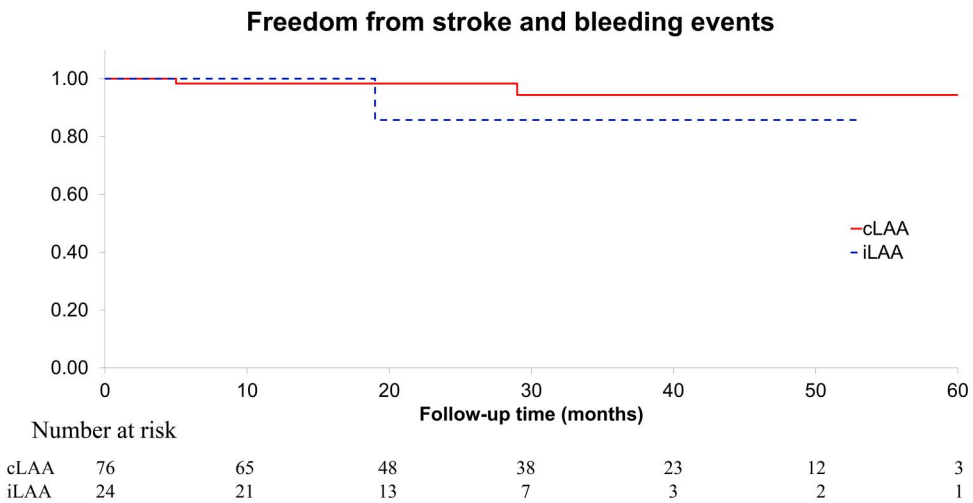

Figure 5. Freedom from Stroke and Bleeding Events

Downloaded from academic.oup.com/icvts/article/40/10/ivaf172/8300855 by guest on 02 October 2026

REFERENCES

[1] Blackshear JL, Odell JA. Appendage obliteration to reduce stroke in cardiac surgical patients with atrial fibrillation. *Ann Thorac Surg*. 1996; 61:755-759.

[2] Manning WJ, Silverman DI, Katz SE, et al. Impaired left atrial mechanical function after cardioversion: relation to the duration of atrial fibrillation. *J Am Coll Cardiol*. 1994;23:1535-1540.

[3] Bonow RO, Carabello BA, Chatterjee K, et al.; 2006 Writing Committee Members; American College of Cardiology/American Heart Association Task Force. 2008 Focused update incorporated into the ACC/AHA 2006 guidelines for the management of patients with valvular heart disease: a report of the American College of Cardiology/American Heart Association Task Force on Practice Guidelines (Writing Committee to Revise the 1998 Guidelines for the Management of Patients With Valvular Heart Disease): endorsed by the Society of Cardiovascular Anesthesiologists, Society for Cardiovascular Angiography and Interventions, and Society of Thoracic Surgeons. *Circulation* 2008; 118:e523-e661.

[4] Richard PW, Emilie PBC, Domenico P, Jeff SH, Katheryn BBS, et al. Left atrial appendage occlusion during cardiac surgery to prevent stroke. *N Engl J Med*. 2021;384:2081-2091.

[5] Katz ES, Tsiamtsiouris T, Applebaum RM, et al. Surgical left atrial appendage ligation is frequently incomplete: a transesophageal echocardiographic study. *J Am Coll Cardiol*. 2000;36:468-471.

[6] García-Fernández MA, Pérez-David E, Quiles J, et al. Role of left atrial appendage obliteration in stroke reduction in patients with mitral valve prosthesis: a transesophageal echocardiographic study. *J Am Coll Cardiol*. 2003;42:1253-1258.

[7] Healey JS, Crystal E, Lamy A, et al. Left Atrial Appendage Occlusion Study (LAAOS): results of a randomized controlled pilot study of left atrial appendage occlusion during coronary bypass surgery in patients at risk for stroke. *Am Heart J*. 2005;150:288-293.

[8] Kanderian AS, Gillinov AM, Pettersson GB, Blackstone E, Klein AL. Success of surgical left atrial appendage closure: assessment by transoesophageal echocardiography. *J Am Coll Cardiol*. 2008;52:924-929.

[9] Subhasis C, John CA, Paul JP, Ted F. Left atrial appendage occlusion: lessons learned from surgical and transcatheter experiences. *ATS*. 2011; 92:2283-2292.

[10] Yabing D, Haitao X, Baotong L, Xin Y, Hansong S. Effects of left atrial appendage surgical treatment on the incidence of ischemic cerebrovascular accidents in patients with atrial fibrillation undergoing cardiac surgery. *J Thorac Cardiovasc Surg*. 2022;164:1106-1116.

[11] Schulman S, Kearon C; Subcommittee on Control of Anticoagulation of the Scientific and Standardization Committee of the International Society on Thrombosis and Haemostasis. Definition of major bleeding in clinical investigations of antihemostatic medicinal products in non-surgical patients. *J Thromb Haemost*. 2005;3:692-694.

[12] Nakamura Y, Nishijima S, Kuroda M, et al. Perfusion strategy using axillary or femoral cannulation for minimally invasive cardiac surgery: experience in 270 patients with computed tomography–based criteria. *Eur J Cardiothorac Surg*. 2021;59:1200-1207.

[13] Nakayama T, Nakamura Y, Yasumoto Y, et al. Early and mid-term outcomes of minimally invasive mitral valve repair via right minithoracotomy: 5-year experience with 129 consecutive patients. Gen Thorac Cardiovasc Surg 2021;69:1174-1184.

[14] Di Biase L, Santangeli P, Anselmino M, et al. Does the left atrial appendage morphology correlate with the risk of stroke in patients with atrial fibrillation? Results from a multicenter study. *J Am Coll Cardiol*. 2012; 60:531-538.

[15] Aryana A, Singh SK, Singh SM, et al. Association between incomplete surgical ligation of left atrial appendage and stroke and systemic embolization. *Heart Rhythm*. 2015;12:1431-1437.

[16] Branzoli S, Marini M, Guarracini F, et al. Epicardial standalone left atrial appendage clipping for prevention of ischemic stroke in patients with atrial fibrillation contraindicated for oral anticoagulation. *J Cardiovasc Electrophysiol*. 2020;31:2187-2191.

[17] Younju R, Sung JP, Jae WL. Epicardial left atrial appendage clip occlusion in patients with atrial fibrillation during minimally invasive cardiac surgery. *J Thorac Cardiovasc Surg*. 2023;166:468-474.

[18] Antaki T, Michaelman J, McGroarty J. Robotics-assisted epicardial left atrial appendage clip exclusion. *JTCVS Techniques*. 2021;9:59-68.

[19] Kuzmin B, Staack T, Wippermann J, Wacker M. Left atrial appendage occlusion device causing coronary obstruction: a word of caution. *J Card Surg*. 2021;36:723-725.

[20] Leinonen JV, Emanuelov AK, Platt Y, et al. Left atrial appendages from adult hearts contain a reservoir of diverse cardiac progenitor cells. *PLoS One*. 2013;8:e59228.

[21] Cruz-Gonzalez I, Yan BP, Lam YY. Left atrial appendage exclusion: state-of the art. *Catheter Cardiovasc Interv*. 2010;75:806-813.

[22] Singh IM, Holmes D. Left atrial appendage closure. *Curr Cardiol Rep*. 2010;12:413-421.

[23] Leal S, Moreno R, de Sousa Almeida M, et al. Evidence-based percutaneous closure of the left atrial appendage in patients with atrial fibrillation. *Curr Cardiol Rev*. 2012;8:37-42.

[24] Alberto C, Miguel A, Horst S, et al. Prevalence of extra-appendage thrombosis in non-valvular atrial fibrillation and atrial flutter in patients undergoing cardioversion: a large transoesophageal echo study. *Euro Intervention* 2019;15:e225-e230.

Downloaded from academic.oup.com/icvts/article/40/10/ivaf172/8300855 by guest on 02 October 2026

© The Author(s) 2025. Published by Oxford University Press on behalf of the European Association for Cardio-Thoracic Surgery.
This is an Open Access article distributed under the terms of the Creative Commons Attribution-NonCommercial License (https://creativecommons.org/licenses/by-nc/4.0/), which permits non-commercial re-use, distribution, and reproduction in any medium, provided the original work is properly cited. For commercial re-use, please contact reprints@oup.com for reprints and translation rights for reprints. All other permissions can be obtained through our RightsLink service via the Permissions link on the article page on our site—for further information please contact journals.permissions@oup.com.
Interdisciplinary CardioVascular and Thoracic Surgery, 2025, 40, ivaf172
https://doi.org/10.1093/icvts/ivaf172
Original article