Check for updates

Original Article

Midterm Outcomes of Minimally Invasive Aortic Valve Replacement via Right Lateral Minithoracotomy

Innovations
2025, Vol. 20(1) 48–56
© The Author(s) 2025
Article reuse guidelines:
sagepub.com/journals-permissions
DOI: 10.1177/15569845241308005
journals.sagepub.com/home/inv
Sage

Akira Furutachi[1], MD, PhD, Yoshitsugu Nakamura[1], MD, PhD, Kusumi Niitsuma[1], MD, Masaki Ushijima[1], MD, Yuto Yasumoto[1], MD, Daiki Yoshiyama[1], MD, Miho Kuroda[1], MD, Kosuke Nakamae[1], MD, Yujiro Hayashi[1], MD, Taisuke Nakayama[1], MD, PhD, Ryo Tsuruta[1], MD, PhD, and Yujiro Ito[1], MD

Abstract

Objective: Minimally invasive aortic valve replacement (MIAVR) procedures have been found to have good short-term results. However, no known reports regarding outcomes of MIAVR via a right lateral minithoracotomy (LT) approach over longer terms have been presented. The aim of the present study was to analyze the midterm outcomes of the use of MIAVR with the right LT approach over an 8-year period. **Methods:** Between September 2014 and February 2023, MIAVR was performed for 348 patients with severe aortic valve stenosis and regurgitation at our hospital. Operative mortality, all-cause mortality, and valve-related events were retrospectively examined. **Results:** The mean patient age was 72.3 ± 10.9 years, while 78 patients (22.4%) were more than 80 years old. Surgical, cardiopulmonary bypass, and cross-clamp times were 194.7 ± 43.2, 118.6 ± 28.7, and 89.4 ± 23.3 min, respectively. The 30-day mortality rate was 0.3%. The mean follow-up period was 35.6 ± 25.9 months. Overall survival shown by Kaplan-Meier analysis at 1, 3, and 5 years was 96.4%, 90.3%, and 83.2%, respectively, and freedom from valve-related events at those time points was noted in 100%, 99.5%, and 96.9% of the cases, respectively. **Conclusions:** MIAVR via a right LT approach was found to be associated with excellent short-term and midterm outcomes and is considered to have the potential to become an established surgical option.

Central Message
Cases of minimally invasive aortic valve replacement via a right lateral minithoracotomy approach were reviewed. Excellent midterm outcomes were noted, including freedom from valve-related events after 5 years in 96.9% of the patients.

Keywords
minimally invasive aortic valve replacement, right lateral minithoracotomy, midterm outcomes

Introduction

Several minimally invasive approaches (e.g., upper and lower ministernotomy, right anterior minithoracotomy) have been developed to reduce the surgical invasiveness of aortic valve replacement (AVR), and better outcomes obtained with these approaches as compared with a full sternotomy have been reported.[1–4] We previously found that minimally invasive AVR (MIAVR) via a right lateral minithoracotomy (LT) approach also has potential for a better outcome than a full sternotomy.[5–7] As compared with a right anterior minithoracotomy (RAT) approach, the distance to the aortic valve with use of the LT is slightly greater, although the aortic valve is more easily seen from the front, thus expanding the indications for this procedure.

Although we have obtained good surgical outcomes with MIAVR using the LT approach, for consideration as a possible alternative to a RAT approach, it is important to confirm that there is no problematic later outcomes over the long term. Few reports have evaluated such late outcomes; thus, the present study was conducted to analyze our 8-year experience with MIAVR via the LT approach.

[1]Department of Cardiovascular Surgery, Chiba-Nishi General Hospital, Japan

Corresponding Author:
Yoshitsugu Nakamura, MD, PhD, Department of Cardiovascular Surgery, Chiba-Nishi General Hospital, 107-1 Kanegasaku Matsudo, Chiba, 270-2251, Japan.
Email: ystgnkmr@gmail.com

Methods

Patients and Study Design

From September 2014 to February 2023, isolated AVR was performed in 459 patients with severe aortic valve stenosis (AS) and aortic insufficiency (AI) at Chiba-Nishi General Hospital in Japan, with MIAVR via the LT approach performed in 348 patients. Data for these cases were collected retrospectively. Patients who underwent left atrial appendage closure were included, whereas those who underwent other surgical procedures were excluded. Preoperative testing in the present cases included pulmonary function, electrocardiogram (ECG), ankle-brachial index, echocardiography, and head and neck magnetic resonance imaging examinations. In addition, coronary artery evaluation was performed using contrast-enhanced computed tomography (CT) synchronized with the ECG, and when lesions were suspected, coronary angiography was conducted. Exclusion criteria for MIAVR included atherosclerotic disease in the ascending aorta, poor left ventricular ejection fraction (<30%), poor lung function (forced expiratory volume during the first second <1 L), and history of right lung surgery. This study was approved on January 26, 2023, by the Tokushukai Group Ethics Committee Review Board (TGE02118-025). Written informed consent was obtained from all patients for publication of the study data.

The outcomes analyzed were 30-day mortality as well as all-cause death and valve-related events during the follow-up period of up to 8 years. Valve-related events included major paravalvular leakage, endocarditis, and/or structural valve deterioration (SVD; increase in mean transvalvular gradient ≥20 mm Hg, resulting in mean gradient ≥40 mm Hg or severe transvalvular regurgitation). Furthermore, the results included early surgical complications, such as reexploration, respiratory insufficiency, acute kidney injury (AKI), cerebrovascular events, surgical site infection, and new postoperative onset atrial fibrillation.

Surgical Techniques

Details regarding the MIAVR procedure via the LT approach (Supplemental Video) have been previously reported.[5–7] Under general anesthesia with differential lung ventilation, each patient was placed in a 45° left lateral position with a pillow under the right thorax. A 5 cm skin incision was performed on the lateral edge of the pectoralis major muscle (Fig. 1) as well as a thoracotomy incision nearly through the third intercostal space, then the right femoral artery and vein were cannulated to establish cardiopulmonary bypass (CPB). If there was risk of cerebral perfusion due to retrograde perfusion present with use of the femoral artery, the right axillary artery was chosen. Under transesophageal echocardiography guidance, right femoral venous cannulation was performed, with vacuum assistance used for venous drainage. Perfusion was controlled from 2.2 to 2.6 L/m^2. A left ventricular venting tube was inserted

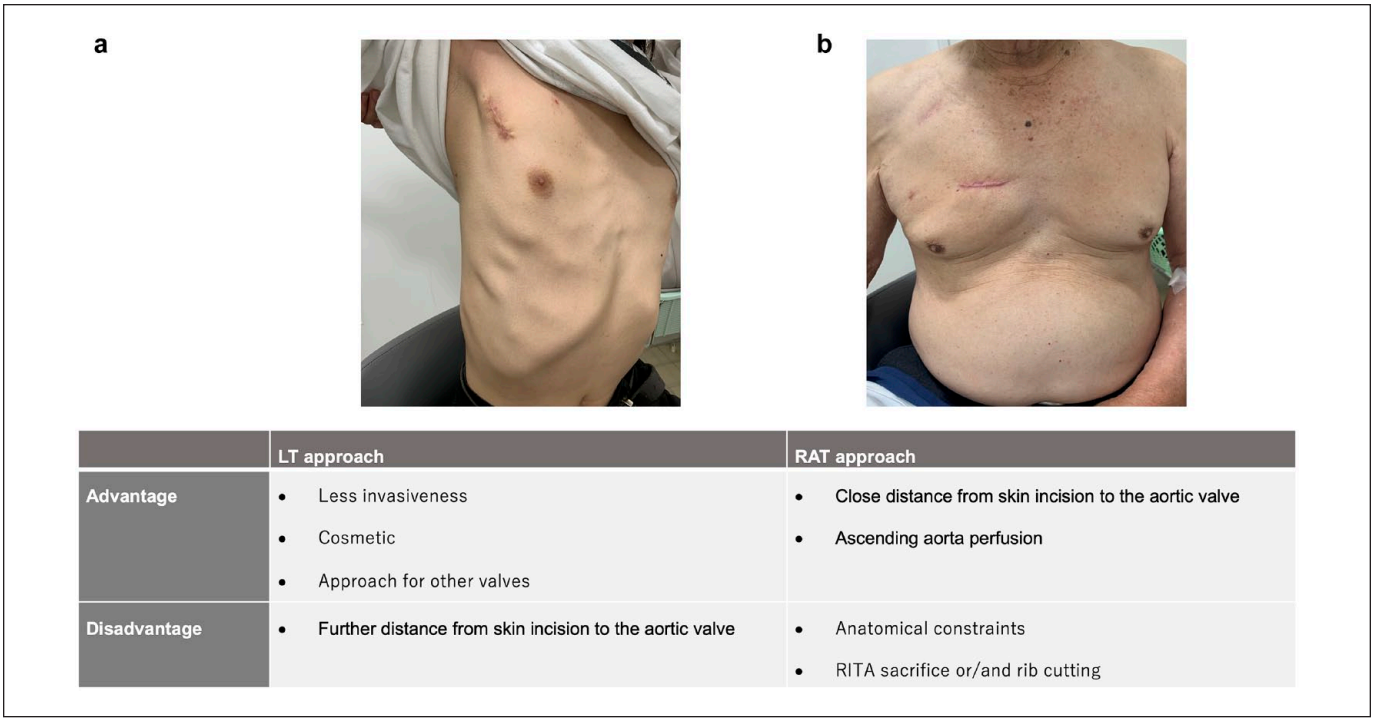

Fig. 1. (a) Representative skin incision for MIAVR via LT approach. (b) Representative skin incision for MIAVR via RAT approach. LT, right lateral minithoracotomy; MIAVR, minimally invasive aortic valve replacement; RAT, right anterior minithoracotomy; RITA, right internal thoracic artery.

from the right upper pulmonary vein through the main incision, and patient blood was cooled to 32 °C. CO_2 insufflation into the right thoracic cavity was performed at a flow rate of 5 L/min. Following insertion of an aortic root cannula, the ascending aorta was cross-clamped using a Cygnet flexible clamp (Péters Surgical, Boulogne-Billancourt, France) through the main incision. Initial cold blood cardioplegia was then administered. For AI cases, 20 mEq of potassium chloride was systemically administered before aortic cross-clamping to reduce myocardial oxygen consumption. After aortic cross-clamping was completed, a transverse aortotomy and selective cardioplegia were performed. Additional cold blood cardioplegia was infused through each coronary ostium every 30 to 40 min. All procedures were performed under direct vision with thoracoscopic assistance. Sutures were tied down with the aid of a knot pusher. The AVR procedure used was the same as that for conventional AVR cases. A Perceval bioprosthetic heart valve (Corcym, London, UK) was used after 2019, when it became available at our hospital for patients over 70 years old and with an anatomically feasible condition.

Statistical Analysis

All statistical analyses were performed using the EZR software package (Saitama Medical Center, Jichi Medical University, Saitama, Japan), which is a graphical user interface for the R software program (The R Foundation for Statistical Computing, Vienna, Austria). Specifically, EZR is a modified version of R commander designed to add statistical functions frequently used in biostatistics.[8] Values are expressed as the mean ± standard deviation. Nominal and categorical variables were compared using a chi-square test and Fisher's exact test, respectively. Continuous variables were compared using a *t* test or the Mann–Whitney *U* test. All *P* values are two-sided, with a value less than 0.05 considered to be statistically significant. All-cause and valve-related event-free survival curves were constructed by analyzing data with the Kaplan–Meier method. Comparisons of types of prosthesis were performed using the Kaplan-Meier method and a log-rank test with the α level set at 0.05.

Results

The preoperative characteristics of all patients are shown in Table 1. The mean patient age was 72.3 ± 10.9 years, and 78 (22.4%) were more than 80 years old, whereas 181 (52.1%) were male patients. The European System for Cardiac Operative Risk Evaluation (EuroSCORE) II was 2.07 ± 2.28. AS was found in 214 patients (61.5%) and AI in 134 patients (38.5%). Operative variables are presented in Table 2. Operation, CPB, and cross-clamp times were 194.7 ± 43.2, 118.6 ± 28.7, and 89.4 ± 23.3 min, respectively. Figure 2 shows the operation time data throughout the study period by year. The operation time was 257.8 min in 2014, but it improved over the years, reaching 147.5 min in 2022. Similar trends were observed in CPB and cross-clamp times. Prosthetic valve type was mechanical prosthesis in 16 cases (4.6%), pericardial bioprosthesis in 299 cases (85.9%), and sutureless bioprosthesis in 33 cases (9.5%). Internally mounted bioprostheses (n = 252) that were used included the Carpentier–Edwards PERIMOUNT Magna Ease pericardial bioprosthesis aortic valve (Edwards Lifesciences, Irvine, CA, USA), the INSPIRIS RESILIA aortic bioprosthesis (Edwards Lifesciences), the Mosaic bioprosthesis (Medtronic, Dublin, Ireland), Avalus™

Table 1. Preoperative Characteristics.

Variable	Value
Age, years	72.3 ± 10.9
Age >80 years	78 (22.4)
Female	167 (47.9)
Height, cm	158.6 ± 9.8
Weight, kg	58.0 ± 11.7
Body surface area, m^2	1.55 ± 0.18
Comorbidities	
Hypertension	239 (68.5)
Diabetes mellitus	70 (20.1)
Chronic kidney disease	84 (24.1)
Hemodialysis	24 (6.9)
NYHA class III or IV	99 (28.4)
Previous cardiac surgery	3 (0.9)
History of cerebrovascular disease	17 (4.9)
Atrial fibrillation	11 (3.2)
Infective endocarditis	5 (1.4)
EuroSCORE II	2.07 ± 2.28
Aortic valve pathology	
AS	214 (61.5)
AI	134 (38.5)

Abbreviations: AI, aortic insufficiency; AS, aortic valve stenosis; EuroSCORE II, European System for Cardiac Operative Risk Evaluation, version II; NYHA, New York Heart Association; SD, standard deviation.
Values are shown as mean ± SD or number (%).

Table 2. Operative Variables.

Variable	Value
Operation time, min	194.7 ± 43.2
Cardiopulmonary bypass time, min	118.6 ± 28.7
Aortic cross-clamp time, min	89.4 ± 23.3
Implanted prosthesis	
Mechanical prothesis	16 (4.6)
Pericardial bioprosthesis	299 (85.9)
Sutureless bioprosthesis (Perceval)	33 (9.5)
Implanted prosthesis size, mm	21.5 ± 2.3
Conversion to sternotomy	0
Arterial cannulation	
Femoral artery	223 (64.1)
Axillary artery	123 (35.3)
Femoral + axillary artery	2 (0.6)

Values are shown as mean ± standard deviation or number (%).

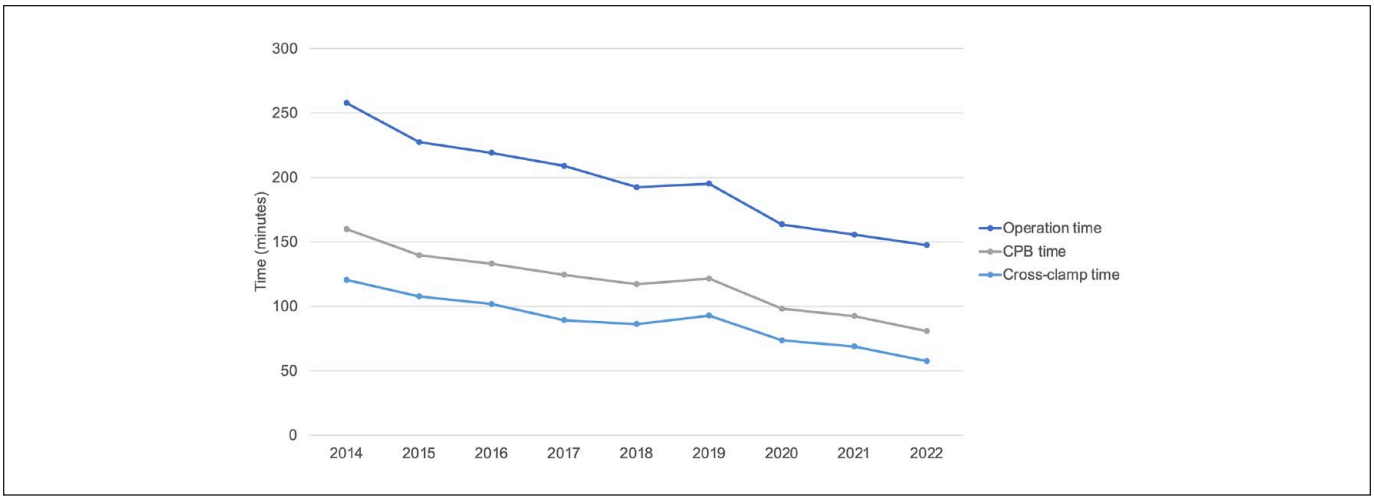

Fig. 2. Changes in operation, CPB, and cross-clamp times over the years. CPB, cardiopulmonary bypass.

bioprosthesis (Medtronic), and Epic™ aortic valve (Abbott, Abbott Park, IL, USA), whereas externally mounted bioprostheses (n = 40) included Mitroflow (Corcym), Crown (Corcym), and Trifecta (Abbott). Cannulation sites were the femoral artery in 223 (64.1%), axillary artery in 123 (35.3%), or both the femoral and axillary artery in 2 (0.6%) cases. Postoperative findings are summarized in Table 3. The 30-day mortality rate was 0.3% (1 of 348), and the average length of hospital stay was 11.4 ± 8.3 days. Intraoperative and postoperative blood transfusions were performed in 86 cases (24.7%). Reexploration and a cerebrovascular event occurred in 1 case (0.3%), respiratory insufficiency occurred in 3 cases (0.8%), AKI occurred in 13 cases (3.6%), surgical site infection occurred in 4 cases (1.1%), and new-onset postoperative atrial fibrillation occurred in 78 cases (22.4%). Furthermore, mild perivalvular leakage was noted in 2 (0.6%), whereas requested pacemaker implant was performed in 1 case (0.3%).

Table 4 shows late-phase outcomes. The mean follow-up period was 35.6 ± 25.9 months. All-cause death was noted in 36 cases during follow-up. Prosthetic valve–related events were observed in 5 patients, with 4 of those related to SVD and 1 prosthetic valve endocarditis. Congestive heart failure was observed in 10 and cerebrovascular events in 8 cases, whereas pacemaker implant was required in 5. Overall actual survival determined by Kaplan–Meier analysis at 1, 3, and 5 years was

Table 3. Postoperative Variables.

Variable	Value
Mortality	1 (0.3)
Intensive care unit stay, days	2.6 ± 1.6
Hospital stay, days	11.4 ± 8.3
Intraoperative or postoperative blood transfusion	86 (24.7)
Reexploration	1 (0.3)
Respiratory insufficiency	4 (1.1)
Acute kidney injury	10 (2.9)
Cerebrovascular accident	1 (0.3)
Surgical site infection	4 (1.1)
New-onset postoperative AF	78 (22.4)
Perivalvular leakage	
Trivial	0
Mild	2 (0.6)
≥Moderate	0
Requested pacemaker implant	1 (0.3)

Abbreviations: AF, atrial fibrillation; SD, standard deviation.
Values are shown as mean ± SD or number (%).

Table 4. Late-Phase Outcomes.

Variable	Value
Follow-up period, months	35.6 ± 25.9
All-cause death	36 (10.3)
Cause of late death	
Cardiac	6 (16.6)
Malignancy	6 (16.6)
Cerebrovascular event	4 (11.1)
Infection	4 (11.1)
Renal	1 (2.8)
Unknown	15 (41.7)
Valve-related event	
Structural valve deterioration	4 (1.1)
Prosthetic valve endocarditis	1 (0.3)
Congestive heart failure	10 (2.9)
Cerebrovascular event	8 (2.3)
Requested pacemaker implant	5 (1.4)

Values are shown as mean ± standard deviation or number (%).

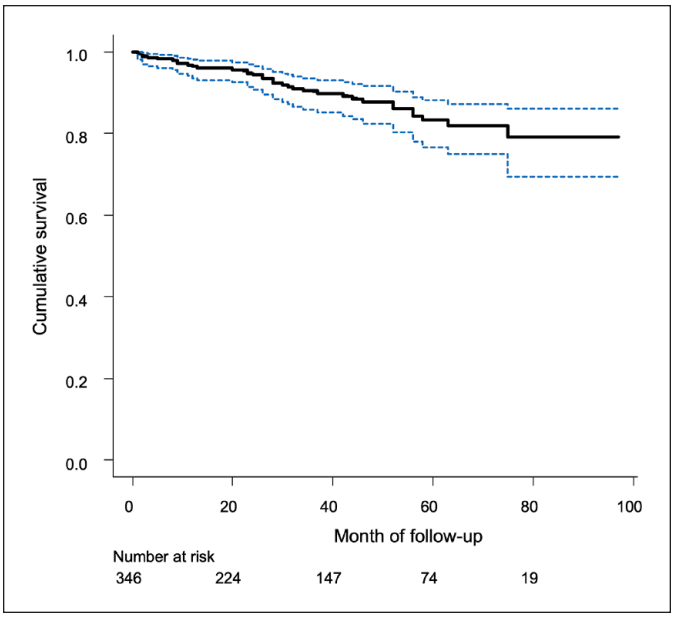

Fig. 3. Results of Kaplan–Meier analysis of overall survival.

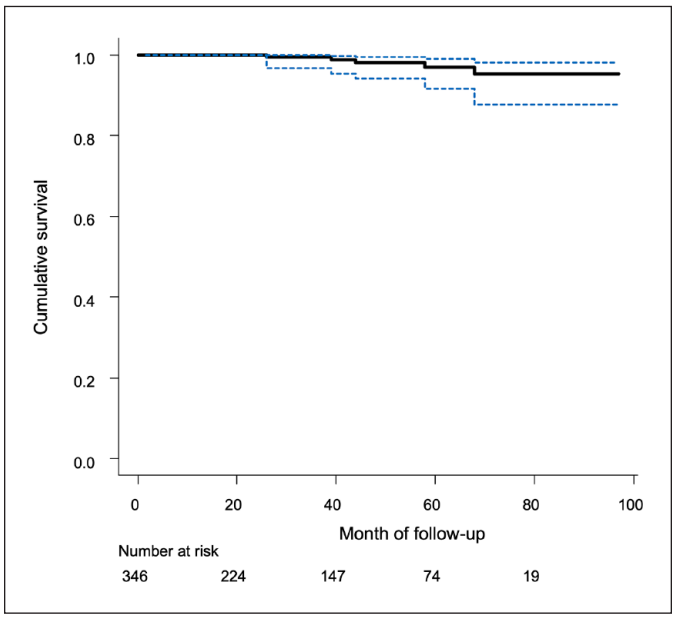

Fig. 4. Results of Kaplan–Meier analysis of valve event-free survival.

96.4%, 90.3%, and 83.2%, respectively (Fig. 3), whereas actual freedom from valve-related events at those time points was 100%, 99.5%, and 96.9%, respectively (Fig. 4). Furthermore, at 1, 3, and 5 years, freedom from valve-related events for cases with an internally mounted bioprosthesis was 100%, 100%, and 98.8%, respectively; for those with an externally mounted bioprosthesis it was 100%, 93.9%, and 87.7%, respectively; and for those with a mechanical prosthesis it was 100%, 100%, and 100%, respectively, whereas freedom from valve-related events for those with a sutureless bioprosthesis at 1 and 3 years was 100% and 87.5%, respectively (Fig. 5). Significantly greater numbers of valve-related events were noted in patients with an externally mounted prosthesis as compared with those with the other types ($P < 0.01$), but excluding Trifecta and Mitroflow, no significant difference was observed in valve-related events.

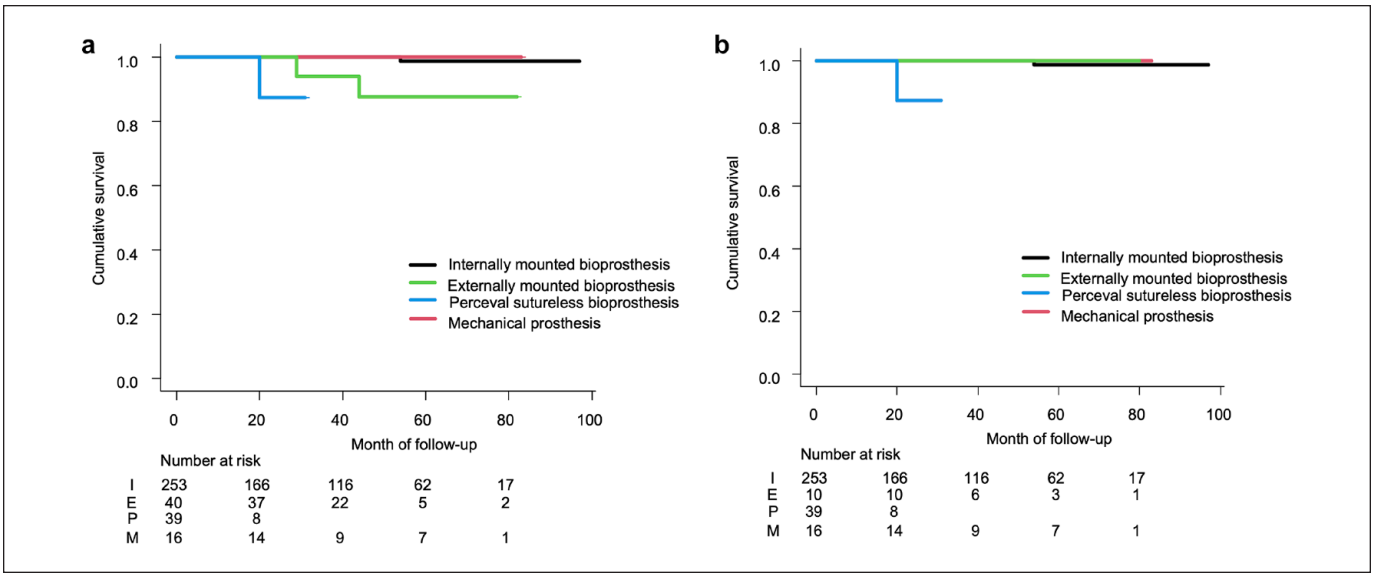

Fig. 5. (a) Results of Kaplan–Meier analysis of valve event-free survival for each type of prosthesis. (b) Results of Kaplan–Meier analysis of valve event-free survival for each type of prosthesis excluding Mitroflow and Trifecta.

Discussion

Recently, minimally invasive cardiac surgery (MICS) has become the standard approach. Along with the increasing popularity of transcatheter aortic valve implantation (TAVI), there is also an increasing need for MIAVR as treatment for aortic valves.

Our approach is similar to the TAX-AVR method previously reported by Ito et al.[9] with regard to the incision and open intercostal space as well as other related factors. Generally, with a TAX-AVR approach, the right upper limb is often positioned in an elevated state. However, our method differs in that the right upper limb is lowered to accommodate perfusion from the right axillary artery. Notably, perfusion from the right axillary artery was performed in 35.3% of the present cases.

While hospital stay length (11.4 days) was slightly longer as compared with that for those other related methods, other reports of cases in Japan have presented similar results.[10–12] The duration of hospital stay in the present study is considered to be average for Japan. Longer stays in Japanese hospitals can possibly be explained by differences in the rate of aging of the population, proportions of individuals living alone, health care system details, and societal customs as compared with those in other countries.

Short-Term Outcomes of LT Approach

Reports of MIAVR via the LT approach are summarized in Table 5.[10,11,13,14] Tokoro et al. noted significantly fewer cases that required blood transfusion when MIAVR via the LT approach was used as compared with conventional AVR.[11] In addition, operative mortality rates have been reported to range from 0% to 0.9%. Together, those findings indicate good short-term outcomes for affected patients, including fewer blood transfusions, shorter hospital stays, and lower operative mortality. On the other hand, when compared with conventional AVR, MIAVR is a time-consuming procedure.[1–4] Nevertheless, Tokoro et al. reported CPB and cross-clamp times for MIAVR via the LT approach that were comparable with those for conventional AVR,[11] as also noted in the present study. Therefore, it is considered that operative, CPB, and cross-clamp times in MIAVR cases are within acceptable limits. Furthermore, although MIAVR is a time-consuming procedure, the present study showed clear improvements over the years. With the proficiency gained through practice, MIAVR can become a surgical procedure equivalent to conventional AVR.

Semsroth et al. reported that 12.7% of their patients underwent conversion to a sternotomy, whereas reexploration for bleeding was required for 12.0%.[13] As an explanation for these findings, they noted that all of the staff surgeons performed MIAVR. Studies presented by Totsugawa et al.[10] and Tokoro et al.[11] found that none of their patients required conversion to a sternotomy or reexploration for bleeding, a finding also observed in the present study. It is thus suggested that proficiency with the required techniques is necessary when performing MIAVR via the LT approach.

Long-Term Outcomes of LT Approach

As compared with TAVI, surgical AVR is inevitably more invasive, and even MIAVR cannot surpass TAVI in terms of minimal invasiveness. On the other hand, an advantage of surgical AVR is good durability.[15–17] When considering the usefulness of MIAVR, attention is inevitably focused on its minimal invasiveness and short-term results, although longer term results are also very important. To the best of our knowledge, no previous reports have provided findings indicating long-term results of MIAVR via the LT approach (Table 5). Results obtained in the present study of 8-year follow-up findings showed that the rate of freedom from valve-related events was 96.9% after 5 years.

The long-term outcome following AVR is influenced by the type of bioprosthesis used. In a study of internally mounted bioprosthesis cases, Shibata et al.[18] reported 5-year rates for freedom from severe and moderate SVD in cases with an Epic porcine bioprosthesis in an aortic position of 100% and 92%, respectively, whereas the study presented by Bavaria et al.[19] noted a 5-year rate of actuarial freedom from SVD in cases with an INSPIRIS RESILIA aortic valve of 100%. In the present study, a 5-year SVD-free rate of 98.8% was noted in patients with an internally mounted bioprosthesis, which is comparable with those reports for a median sternotomy approach. On the other hand, the 5-year SVD-free rate for an externally mounted bioprosthesis was 87.7%, significantly lower than that for cases with an internally mounted bioprosthesis. Early failure due to leaflet tear has been reported for Trifecta valves,[20] with the same finding noted in the present series. Thus, the difference between LT and a median sternotomy approach does not appear to be the result of late outcome differences, as results after 5 years in the present analysis were equivalent. We hope to report the findings obtained after longer terms in the future.

RAT Versus LT Approach

Several different methods are available for such cases, including a partial sternotomy and the RAT approach,[2,3,16,17,21] with differences between the LT and RAT approaches presented in Figure 1. Important advantages of the LT approach are a lower level of invasiveness and better cosmetic results, as the right internal thoracic artery (RITA) is preserved, and no ribs are cut. We consider that RITA and rib preservation also contribute to reduce blood loss. Another key advantage is that surgical visualization is better with the LT approach, as there are fewer anatomical constraints, and the aortic valve can be viewed under direct vision. When the aorta and aortic valves are located to the left of the sternum, the LT approach can have considerable visual field limitations. We previously reported that the use of a sutureless aortic valve with the LT approach may be more useful than with the RAT approach, because the aortic valve can be seen under direct vision.[5] Improved visualization of the aortic annulus is more important than remoteness. For deployment of a Perceval valve, coaxiality between the axis of the Perceval Dual MICS holder and that from the skin incision to the aortic annulus is crucial; thus it is considered that the LT

Table 5. Other Reports of MIAVR via Right Lateral Minithoracotomy Approach.

	Totsugawa et al.[10]	Semsroth et al.[13]	Tokoro et al.[11]	Tokoro et al.[11]	Taghizadeh-Waghefi et al.[14]	Present study
Cases	21	166	47 (endoscopic AVR)	157 (TAX-AVR)	426	348
Arterial cannulation site	FA 100% Additional Ax 14%	FA 91% Ascending aorta 9%	FA 100%	FA 100%	FA 100%	FA 64.1% Ax 35.3% FA + Ax 0.6%
RDV use	0	NA	0	0	349 (81.9%)	33 (9.5%)
CPB time, min	155 ± 23	137	132	139	66.4 ± 18.5	118.6 ± 28.7
Cross-clamp time, min	105 ± 15	93	95	99	43.5 ± 14.4	89.4 ± 23.3
Blood transfusion	8 (38%)	58 (34.9%)	1.2 units	2.7 units	0.6 ± 1.6 RBC units	86 (24.7%)
Conversion to sternotomy	0	21 (12.7%)	0	0	7 (1.6%)	0
Postoperative stroke	0	1 (0.6%)	0	3 (1.9%)	10 (2.3%)	1 (0.3%)
Reexploration for bleeding	0	20 (12.0%)	0	2 (1.3%)	39 (9.2%)	1 (0.3%)
Hospital stay after surgery, days	16.2 ± 3.9	NA	7.4	10.0	9.3 ± 5.0	11.4 ± 8.3
Mortality	0	4% (90-day)	0	0	4 (0.9%)	1 (0.3%)
Late outcome	Not assessed	5-year survival rate 85%	Not assessed	Not assessed	Not assessed	5-year freedom from valve-related events 96.9%

Abbreviations: Ax, axillary artery; CPB, cardiopulmonary bypass; FA, femoral artery; MIAVR, minimally invasive aortic valve replacement; NA, not applicable; RBC, red blood cell; RDV, rapid deployment valve; TAX-AVR, trans-right axillary aortic valve replacement.
Values are expressed as absolute number, percentage, median, or mean ± SD.

approach is a better technique to use for such cases. An additional advantage is that it is possible to treat other valves such as the mitral valve with use of the LT approach.

On the other hand, it is difficult to approach valves other than the aortic valve with the RAT approach, and a disadvantage of the LT approach is the greater distance from the skin incision to the aortic valve. This may increase the difficulty of the surgical procedure, although thoracoscopic assistance and use of a sutureless aortic valve can be helpful. Another disadvantage of the LT approach is difficulty with perfusion to the ascending aorta. Patients with AS are often affected by a thoracoabdominal aortic atheroma, making the choice of the arterial cannulation site problematic when considering MIAVR. It is difficult to insert an arterial cannula into the ascending aorta through a small wound, and the axillary artery is an important perfusion site. With the LT approach, we position the patient for incision of the right subclavian so as to allow for selection of the right axillary artery as the arterial cannulation site.[22,23] In 35.3% of the present cases, right axillary artery cannulation was used for antegrade perfusion because of the presence of a thoracoabdominal aortic atheroma. Cerebrovascular accidents are the most important complications to avoid; thus, it seems important to position the body with use of the axillary artery in mind to avoid limiting the indications for MIAVR. Although the RAT approach is considered superior in terms of surgical difficulty, the LT approach is likely better in regard to amount of injury to the chest wall and versatility.

El-Sayed Ahmad et al. reported on video-assisted MIAVR through a RAT approach.[24] They reported CPB time and cross-clamp time as 79 ± 38 min and 41 ± 17 min, respectively, which were shorter than our results. In addition, they reported 0% mortality, 0% rethoracotomy for bleeding, 0% RITA injury, and a 1% wound-healing disorder rate, demonstrating excellent outcomes. Although this method appears highly useful, even with an endoscopic approach, the RAT approach tends to have poor visibility in patients with a short sternum-to-spine distance, a common body type among Japanese individuals. Therefore, it cannot be conclusively stated whether the endoscopic RAT approach or direct vision lateral approach is superior, as the choice may vary depending on patient background and the preferences of each facility.

In the present study, the midterm primary outcomes of MIAVR were found to be equivalent to those of a full sternotomy approach. In addition, when compared with conventional AVR results reported by Tokoro et al.[11] and Hiraoka et al.,[25] MIAVR showed improvements in "softer" outcomes, such as hospital stay of 11.4 ± 8.3 versus 19.7 ± 7.8 days, blood transfusion of 24.7% versus 84.1%, and new-onset atrial fibrillation

rate of 22.4% versus 43.5%. Reports from the Japan Cardiovascular Surgery Database in 2017 and 2018, also indicated that MIAVR resulted in improved "softer" outcomes, including decreases in the incidence of renal failure (0.8% vs 2.6%) and infections (1.3% vs 3.2%) and also shorter intensive care unit stay (median 2 vs 3 days) and postoperative length of stay (median 15 vs 22 days).[12] Although the present era is dominated by minimally invasive TAVI, MIAVR that improves "softer" outcomes while maintaining the primary outcome may become the standard surgical procedure in the near future.

Study Limitations

The present study has several limitations. First, it was performed as a nonrandomized, retrospective, observational investigation. Also, although cases treated over an 8-year period at our hospital were included, the mean follow-up period was only 35 months, which is too short to examine the late-phase outcomes of MIAVR. Furthermore, a variety of prostheses were used for these cases, which may have been related to differences in performance. Finally, late-phase outcomes of the sutureless bioprosthesis usage could not be analyzed, because that did not become available at our hospital until after 2019.

Conclusions

MIAVR via a right minithoracotomy approach can provide excellent midterm as well as short-term outcomes and has the potential to become an established surgical option.

Declaration of Conflicting Interests

The authors declared no potential conflicts of interest with respect to the research, authorship, and/or publication of this article.

Funding

The authors received no financial support for the research, authorship, and/or publication of this article.

ORCID iDs

Akira Furutachi https://orcid.org/0000-0001-7328-812X
Daiki Yoshiyama https://orcid.org/0009-0001-3648-8621

Supplemental Material

Supplemental material for this article is available online.

References

1. Ogami T, Yokoyama Y, Takagi H, et al. Minimally invasive versus conventional aortic valve replacement: the network meta-analysis. *J Card Surg* 2022; 37: 4868–4874.
2. Brown ML, McKellar SH, Sundt TM, et al. Ministernotomy versus conventional sternotomy for aortic valve replacement: a systematic review and meta-analysis. *J Thorac Cardiovasc Surg* 2009; 137: 670–679.
3. Furukawa N, Kuss O, Aboud A, et al. Ministernotomy versus conventional sternotomy for aortic valve replacement: matched propensity score analysis of 808 patients. *Eur J Cardiothorac Surg* 2014; 46: 221–227.
4. Gilmanov D, Bevilacqua S, Murzi M, et al. Minimally invasive and conventional aortic valve replacement: propensity score analysis. *Ann Thorac Surg* 2013; 96: 837–943.
5. Nakamura Y, Narita T, Kuroda M, et al. Sutureless aortic valve replacement through lateral mini-thoracotomy - feasibility and effectiveness. *Circ J* 2022; 86: 1733–1739.
6. Masuda T, Nakamura Y, Ito Y, et al. The learning curve of minimally invasive aortic valve replacement for aortic valve stenosis. *Gen Thorac Cardiovasc Surg* 2020; 68: 565–570.
7. Ito Y, Nakamura Y, Yasumoto Y, et al. Surgical outcomes of minimally invasive aortic valve replacement via right mini-thoracotomy for hemodialysis patients. *Gen Thorac Cardiovasc Surg* 2022; 70: 439–444.
8. Kanda Y. Investigation of the freely available easy-to-use software 'EZR' for medical statistics. *Bone Marrow Transplant* 2013; 48: 452–458.
9. Ito T, Maekawa A, Hoshino S, et al. Right infraaxillary thoracotomy for minimally invasive aortic valve replacement. *Ann Thorac Surg* 2013; 96: 715–717.
10. Totsugawa T, Kuinose M, Hiraoka A, et al. Anterolateral approach for minimally invasive aortic valve replacement. *Gen Thorac Cardiovasc Surg* 2014; 62: 290–295.
11. Tokoro M, Sawaki S, Ozeki T, et al. Totally endoscopic aortic valve replacement via an anterolateral approach using a standard prosthesis. *Interact Cardiovasc Thorac Surg* 2020; 30: 424–430.
12. Abe T, Kumamaru H, Nakano K, et al. Status of cardiovascular surgery in Japan between 2017 and 2018: a report based on the Japan Cardiovascular Surgery Database. 3. Valvular heart surgery. *Asian Cardiovasc Thorac Ann* 2021; 29: 300–309.
13. Semsroth S, Matteucci Gothe R, Heinz A, et al. Comparison of anterolateral minithoracotomy versus partial upper hemisternotomy in aortic valve replacement. *Ann Thorac Surg* 2015; 100: 868–873.
14. Taghizadeh-Waghefi A, Arzt S, Wenzel L, et al. Right anterior versus right transaxillary access for minimally invasive aortic valve replacement: a propensity matched competitive analysis. *J Clin Med* 2024; 13: 985.
15. Reardon MJ, Van Mieghem NM, Popma JJ, et al. Surgical or transcatheter aortic-valve replacement in intermediate-risk patients. *N Engl J Med* 2017; 376: 1321–1331.
16. Patel K, Omar W, Gonzalez PE, et al. Expansion of TAVR into low-risk patients and who to consider for SAVR. *Cardiol Ther* 2020; 9: 377–394.
17. Minakata K, Tanaka S, Okawa Y, et al. Long-term outcome of the Carpentier-Edwards pericardial valve in the aortic position in Japanese patients. *Circ J* 2014; 78: 882–889.
18. Shibata K, Maeda S, Kashiyama N, et al. Long-term valve performance of St Jude Medial Epic porcine bioprosthesis in aortic position. *J Artif Organs* 2024; 27: 131–137.
19. Bavaria JE, Griffith B, Heimansohn DA, et al. Five-year outcomes of the COMMENCE trial investigating aortic valve replacement with RESILIA tissue. *Ann Thorac Surg* 2023; 115: 1429–1436.
20. Werner P, Gritsch J, Scherzer S, et al. Structural valve deterioration after aortic valve replacement with the Trifecta valve. *Interact Cardiovasc Thorac Surg* 2021; 32: 39–46.
21. Yamazaki M, Yoshitake A, Takahashi T, et al. Stonehenge technique is associated with faster aortic clamp time in group of minimally invasive aortic valve replacement via right infra-axillary thoracotomy. *Gen Thorac Cardiovasc Surg* 2018; 66: 700–706.

22. Nishijima S, Nakamura Y, Yoshiyama D, et al. Single direct right axillary artery cannulation using a modified Seldinger technique in minimally invasive cardiac surgery. *Gen Thorac Cardiovasc Surg* 2022; 70: 954–961.
23. Nakamura Y, Nishijima S, Kuroda M, et al. Perfusion strategy using axillary or femoral cannulation for minimally invasive cardiac surgery: experience in 270 patients with computed tomography-based criteria. *Eur J Cardiothorac Surg* 2021; 59: 1200–1207.
24. El-Sayed Ahmad A, Salamate S, Amer M, et al. The first 100 cases of two innovations combined: video-assisted minimally invasive aortic valve replacement through right anterior mini-thoracotomy using a novel aortic prosthesis. *Adv Ther* 2021; 38: 2435–2446.
25. Hiraoka A, Kuinose M, Chikazawa G, et al. Minimally invasive aortic valve replacement surgery: comparison of port-access and conventional standard approach. *Circ J* 2011; 75: 1656–1660.