Push down the membranous septum to reduce pacemaker need: A simple deployment technique in sutureless aortic valve replacement

Check for updates

Taisuke Nakayama, MD, PhD,[a] Yoshitsugu Nakamura, MD, PhD,[a] Yuka Higuma, MD,[a] Akihiro Higashino, MD,[a] and Nobuyuki Inoue, MD, PhD,[b] Matsudo and Shinjuku, Japan

From the [a]Department of Cardiovascular Surgery, Chiba-Nishi General Hospital, Matsudo, Japan; and [b]Department of Cardiovascular Surgery, Center Hospital of the National Center for Global Health and Medicine, Shinjuku, Japan.

This study was approved by the Chiba-Nishi General Hospital IRB for a retrospective analysis of deidentified data (IRB/ERB TGE02016-025, approved Sep 12, 2022). Informed consent for publication of clinical data was obtained from all subjects.

Received for publication Dec 1, 2024; revisions received Jan 17, 2025; accepted for publication Jan 28, 2025; available ahead of print Feb 7, 2025.

Address for reprints: Yoshitsugu Nakamura, MD, PhD, Department of Cardiovascular Surgery, Chiba-Nishi General Hospital, 107-1 Kanegasaku Matsudo-shi, Chiba-Ken, 270-2251, Japan (E-mail: ystgnkmr@gmail.com).

JTCVS Techniques 2025;30:48-51

2666-2507

Copyright © 2025 The Author(s). Published by Elsevier Inc. on behalf of The American Association for Thoracic Surgery. This is an open access article under the CC BY-NC-ND license (http://creativecommons.org/licenses/by-nc-nd/4.0/).

https://doi.org/10.1016/j.xjtc.2025.01.020

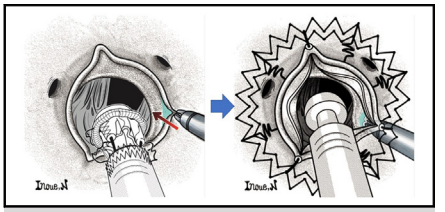

Deploying the sutureless valve while holding right coronary cusp-noncoronary cusp remnant prevents conduction compression.

CENTRAL MESSAGE

Sutureless aortic valve replacement utilizing a technique that pushes down the membranous septum is a simple and effective approach that may reduce the need for permanent pacemaker implantation.

Video clip is available online.

The sutureless Percival valve (Corcym) provide good clinical outcomes,[1,2] but is associated with a relatively high incidence of permanent pacemaker implantation (PPI) due to postoperative atrioventricular block (AVB).[3] Eusanio and colleagues[3] reported a 10.4% rate of AVB requiring pacemaker implantation, with PPI rates decreasing from 17.2% in 2007-2008 to 5.4% in 2016 ($P = .02$). This decline is attributed to the learning curve, particularly in procedural steps and valve sizing. By improving implantation techniques, complications like complete AVB (CAVB) can be reduced.

We have developed a simple, novel method for valve deployment to reduce CAVB during sutureless valve implantation in the standard position.

SURGICAL TECHNIQUE

Surgical aortic valve replacement (SAVR) with a Perceval valve is performed via right mini-thoracotomy or median sternotomy (Video 1). After removing calcification from the native aortic valve, the appropriate valve size is selected using a sizing device. The membranous septum (MS) is assessed and confirmed visually (Figure 1, *A*). During implantation, the commissure between the noncoronary and right coronary cusps is pushed toward the left ventricle, allowing the mitral valve leaflets to shift slightly without deforming the prosthetic valve (Figure 1, *B*). In this technique, the MS is displaced downward using forceps until the inflow ring is fully opened. The forceps are then released, and the outflow ring is deployed. After confirming the leaflet position below the annular inflow, balloon dilation is performed (Figure 1, *C*). No instances of MS rebound have been observed with this method.

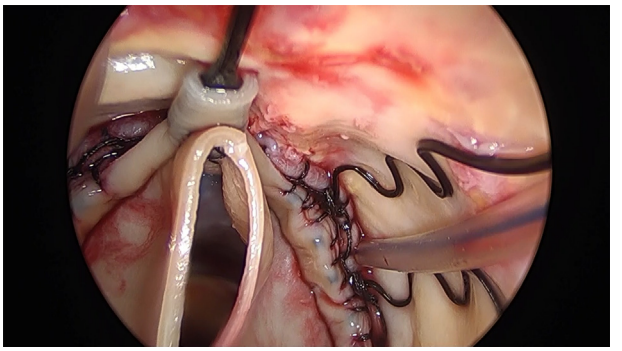

VIDEO 1. Deployment of the sutureless valve with retraction of the membranous septum toward the left ventricular side. Postdeployment evaluation reveals a clear view of the septal valve positioned beneath the inflow ring. Video available at: https://www.jtcvs.org/article/S2666-2507(25)00059-8/fulltext.

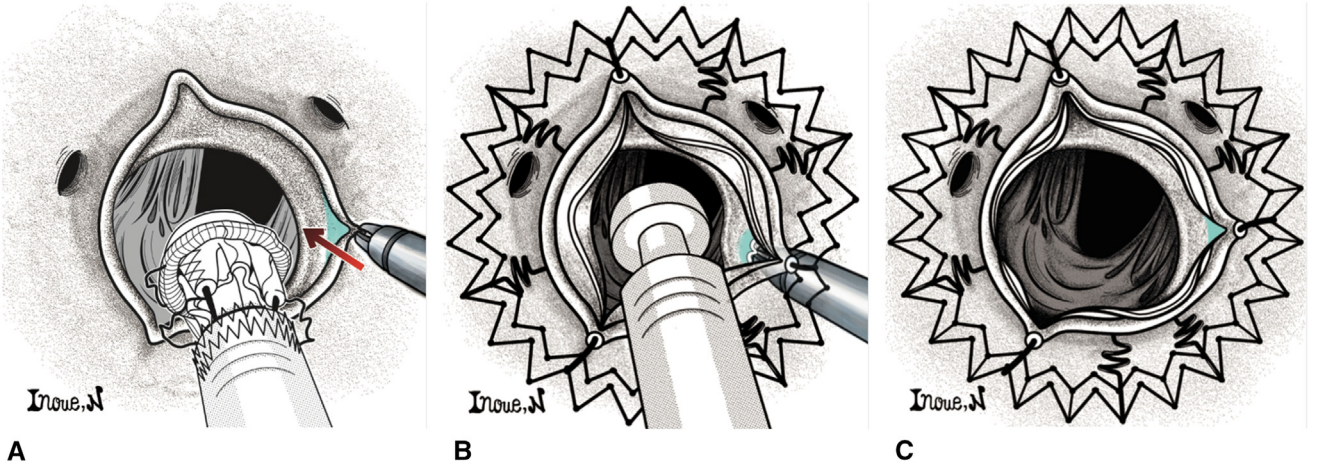

FIGURE 1. Intraoperative view of sutureless valve implantation technique. A, The triangular configuration of the valve cusps between the right and noncoronary valve annuli. The membranous septum (*blue triangle*) is retracted toward the left ventricular side using forceps (*thick red arrow*). B, The sutureless valve is deployed while maintaining the membranous septum in a retracted position toward the left ventricular side. C, The membranous septum, located at the fusion of the right and noncoronary cusps, is visualized below the inflow ring.

Between August 2020 and August 2024, a total of 120 sutureless SAVRs were performed (Table 1), excluding bicuspid valve cases and valve-in-valve procedures following SAVR. There were no cases of valve migration, aortic injury, or the need for PPI during hospitalization. During a mean follow-up period of 16.3 months, AVB necessitating PPI was observed in 1 patient (0.8%) at 4 months postoperation. Postoperative echocardiography revealed mild paravalvular regurgitation in 2 patients (1.6%). Prior to the adoption of this technique (May 2019 to July 2020), 45 patients underwent Perceval SAVR, of whom 1 patient (2.2%) required inpatient PPI and 3 patients (6.7%) required PPI during the late follow-up phase. Despite differences in follow-up duration, the late-phase PPI rate showed a statistically significant reduction, suggesting that this procedural modification may have contributed to the improved outcomes (Table 1). Details of the statistical analysis are provided in Appendix E1.

This study was approved by the Chiba-Nishi General Hospital IRB for retrospective analysis of de-identified data (IRB/ERB TGE02016-025, approved Sept 12, 2022). Informed consent for publication of clinical data was obtained from all subjects.

COMMENT

Fabre and colleagues[4] proposed a modified implantation protocol for reducing postoperative PPI by positioning the sutureless valve higher, avoiding oversizing, and omitting ballooning. However, in SAVR, removing the native valve and annular calcifications makes higher valve positioning challenging because of the risk of prosthetic valve migration. Additionally, avoiding oversizing and balloon dilation may increase the risk of paravalvular regurgitation.

In contrast, we developed a simple technique to prevent postoperative AVB by displacing the MS during sutureless valve implantation. This method moves the valve away from the conduction system while remaining at the level of the 3 aortic valve nadirs, which reduces the risk of conduction disturbances without valve migration. Importantly, the implantation position and use of balloon dilation are consistent with the standard technique, addressing concerns about postoperative paravalvular regurgitation.

Brookes and colleagues[5] identified several risk factors for PPI after sutureless SAVR, including preexisting right bundle branch block, prolonged QRS complex, and prolonged PR interval. Comparing our data with theirs, our cohort included 5 patients (4.2%) with right bundle branch block, 11 patients (9.2%) with a prolonged QRS interval (>120 ms), and 13 patients (12.7%) with a prolonged PR interval (>200 ms). In our study, no cases of new PPI occurred during the hospitalization period (Table 1). The single patient requiring PPI in the late postoperative period had no other risk factors besides a prolonged QRS interval of 100 ms. Our technique has been shown to provide sufficient efficacy, even in patients at risk for PPI, as highlighted in previous studies.

Ueki and colleagues[6] described a similar sutureless valve technique using a thoracoscope to assess the valve's position relative to the MS. Their method involves manually adjusting the MS after the valve is fully deployed. This approach allows for fine-tuning of the prosthesis and may help prevent CAVB.

Our simple implantation technique, which does not require the use of specialized instruments, is both safe and reproducible. Furthermore, it is anticipated to significantly reduce the incidence of PPI following sutureless SAVR.

TABLE 1. Patient characteristics

Characteristic	Prior Perceval SAVR (N = 45)	Push-down Perceval SAVR (N = 120)	*P* value
Age, y, mean ± SD	77.8 ± 5.0	76.6 ± 5.0	.16
Age >80 y, *n* (%)	17 (38)	25 (20.8)	**.03**
Female sex, *n* (%)	22 (49)	59 (49.2)	.97
BSA, m^2, mean ± SD	1.52 ± 0.15	1.52 ± 0.18	.82
EuroSCORE II, mean ± SD	2.6 ± 1.7	3.5 ± 3.1	.08
NYHA class > III, *n* (%)	7 (15.6)	26 (21.7)	.38
Chronic kidney disease, *n* (%)	16 (36.6)	41 (34.2)	.87
HD, *n* (%)	9 (20)	23 (19.2)	.9
Redo surgery	1 (2.2)	9 (7.5)	.21
Post-SAVR	1 (2.2)	4 (3.3)	
Post-CABG		3 (2.5)	
Post- Bentall		2 (1.7)	
Valve size, *n* (%)			
Small	20 (44.4)	54 (45)	.95
Medium	13 (28.9)	43 (36)	.4
Large	11 (24.4)	20 (17)	.25
Extra large	1 (2.2)	3 (2)	.92
Concomitant surgery, *n* (%)	20 (44.4)	44 (36.7)	.36
CABG	14 (31.1)	20 (16.7)	**.04**
MVP	3 (6.7)	9 (7.5)	.85
Cross-clamp time, min, mean ± SD	70.8 ± 23.3	63.8 ± 22.9	.08
Bypass time, min, mean ± SD	106.8 ± 34.7	101.4 ± 34.9	.37
Preoperative electrocardiography			
PR interval, ms, mean ± SD	180 ± 32.2	173 ± 25.4	.16
First-degree heart block, *n* (%)	7 (15.6)	13 (12.7)	.41
QRS duration, ms, mean ± SD	103 ± 22.9	98 ± 18.2	.2
QRS >100, *n* (%)	18 (40)	44 (36.7)	.69
QRS >120, *n* (%)	7 (15.6)	11 (9.2)	.24
LBBB, *n* (%)	1 (2.2)	5 (4.2)	.55
RBBB, *n* (%)	7 (15.6)	5 (4.2)	**.01**
Atrial fibrillation, *n* (%)	5 (11.1)	21 (17.55)	.26
Follow-up, mo, mean ± SD	35.3 ± 15.6	16.3 ± 12.5	**<.01**
Postoperative PPI, *n* (%)			
Implantation during hospitalization	1 (2.2)	0 (0)	.1
Implantation after discharge	3 (6.7)	1 (0.7)	**.03**
Paravalvular regurgitation, *n* (%)	1 (2.2) (grade: mild)	2 (1.7) (grade: mild)	.81

Bold type indicates statistical significance. *SAVR*, Surgical aortic valve replacement; *BSA*, body surface area; *NYHA*, New York Heart Association; *HD*, hemodialysis; *CABG*, coronary artery bypass grafting; *MVP*, mitral valve plasty; *LBBB*, left bundle branch block; *RBBB*, right bundle branch block; *PPI*, permanent pacemaker implantation.

Conflict of Interest Statement

The authors reported no conflicts of interest.

The *Journal* policy requires editors and reviewers to disclose conflicts of interest and to decline handling or reviewing manuscripts for which they may have a conflict of interest. The editors and reviewers of this article have no conflicts of interest.

References

1. Nakamura Y, Narita T, Kuroda M, et al. Sutureless aortic valve replacement through lateral mini-thoracotomy: feasibility and effectiveness. *Circ J*. 2022;86:1733-1739.
2. Nakayama T, Nakamura Y, Yasumoto Y, Gersak B. Sutureless aortic valve for re-operative aortic valve replacement as an alternative to composite graft replacement. *JTCVS Tech*. 2024;24:50-52.
3. Eusanio MD, Phan K, Berretta P, et al. Sutureless and rapid-deployment aortic valve replacement international registry (SURD-IR): early results from 3343 patients. *Eur J Cardiothorac Surg*. 2018;54(4):768-773.
4. Fabre O, Radutoiu M, Carjaliu I, Rebet O, Gautier L, Hysi I. Recent improvement in operative techniques lead to lower pacemaker rate after Perceval implant. *Interact Cardiovasc Thorac Surg*. 2022;35:ivac182.
5. Brookes JDL, Mathew M, Brookes EM, Jaya JS, Almeida AA, Smith JA. Predictors of pacemaker insertion post-sutureless (Perceval) aortic valve implantation. *Heart Lung Circ*. 2021;30:917-921.
6. Ueki C, Nakanaga H, Tabata M. Repositioning of the membranous septum to minimize pacemaker implantation after sutureless surgical aortic valve replacement. *JTCVS Tech*. 2023;19:38-40.

APPENDIX E1

Statistical analysis was performed using an Excel statistical software package (Ekuseru-Toukei; Social Survey Research Information Co, Ltd). Continuous variables are shown as mean ± SD or median (IQR), and categorical variables are shown as number and percentage. The Student *t* test, paired *t* test, or Mann-Whitney *U* test was used for continuous variables, and the χ^2 or Fisher exact test was used for categorical variables.