Circulation Journal
Circ J 2024; 88: 1973–1979
doi:10.1253/circj.CJ-24-0142

ORIGINAL ARTICLE
Surgery

Effect of Narrow Chest on Minimally Invasive Mitral Valve Surgery via Right Minithoracotomy

Shintaro Sawa, MD; Yoshitsugu Nakamura, MD, PhD; Taisuke Nakayama, MD, PhD; Miho Kuroda, MD; Kosuke Nakamae, MD; Kusumi Niitsuma, MD; Masaki Ushijima, MD; Yuto Yasumoto, MD; Daiki Yoshiyama, MD; Akira Furutachi, MD, PhD; Yujiro Ito, MD; Ryo Tsuruta, MD, PhD

Background: The effect of a narrow chest on minimally invasive mitral valve surgery (MIMVS) is unclear.

Methods and Results: We enrolled 206 MIMVS patients and measured anteroposterior diameter (APD) between the sternum and vertebra, transverse thoracic diameter (TD), right and left APD of the hemithorax (RD and LD, respectively), and the Haller index (HI; TD/APD ratio) on computed tomography. Preoperative characteristics and operative outcomes were compared between patients with a narrow chest (Group N; HI >2.5; n=53) and those with a normal chest (control [C]; HI ≤2.5; n=153), and the correlations of these measurements with operation time were evaluated in 133 patients undergoing an isolated mitral procedure. Groups N and C differed significantly in APD (89.4 vs. 114.3 mm, respectively; P<0.001), TD (251.5 vs. 240.3 mm, respectively; P=0.002), RD (152.5 vs. 172.5 mm, respectively; P<0.001), LD (155.0 vs. 172.4 mm, respectively; P<0.001), and HI (2.84 vs. 2.12, respectively; P<0.001). Procedural characteristics were comparable, except for a longer aortic cross-clamp time (ACCT) in Group N (118.7 vs. 105.8 min; P=0.047). Rates of surgical death, re-exploration, cerebral infarction, and prolonged ventilation were comparable between the 2 groups. TD was significantly correlated with ACCT (R^2=0.037, P=0.028) in patients undergoing an isolated mitral procedure.

Conclusions: Early MIMVS outcomes in patients with narrow chests are satisfactory. TD prolongs ACCT during MIMVS.

Key Words: Chest deformity; Minimally invasive cardiac surgery; Minithoracotomy; Mitral valve

Minimally invasive mitral valve surgery (MIMVS) in patients with a narrow chest may be limited by exposure of the mitral valve or surgical maneuvers.[1,2] Although surgeons empirically know that a narrow chest can make MIMVS challenging, this has not yet been proven statistically in any study.

A funnel chest is a typical thoracic deformity characterized by a narrow chest. The Haller index (HI), which was first reported by Haller et al,[3] is widely used as an indicator of the severity of chest narrowing.[4]

In the present study, the presence of a narrow chest was determined by the HI, and we examined the early outcomes of MIMVS in patients with a narrow chest, as well as the effects of the anatomical features of the thoracic cavity on the operative time for MIMVS.

Methods

Ethics Statement

This study adhered to the Declaration of Helsinki and was approved by the Tokushukai Group Ethics Committee (No. TGE01969-025, 2023). All the participants provided informed consent.

Study Design and Patient Population

Of the 229 consecutive patients who underwent MIMVS at Chibanishi General Hospital between 2014 and 2020, 23 who underwent concomitant aortic valve replacement were excluded from this study. This left 206 patients for inclusion in the present study, including those who underwent concomitant procedures other than aortic valve replacement. The guidelines of the Japanese Circulation Society were followed for echocardiographic diagnosis and determining indications for surgery of mitral valve disease.[5,6]

The following parameters were measured on preoperative computed tomography (CT) in all patients: anteroposterior diameter (APD) between the sternum and vertebra, transverse thoracic diameter (TD), and APDs of the right (RD) and left (LD) hemithorax. The HI was calculated as the ratio of TD to APD (i.e., HI=TD/APD). The asymmetry index (AI), which reflects the asymmetry in the tho-

Received February 18, 2024; revised manuscript received April 15, 2024; accepted April 22, 2024; J-STAGE Advance Publication released online May 30, 2024 Time for primary review: 28 days
Department of Cardiovascular Surgery, Chibanishi General Hospital, Matsudo, Japan
Mailing address: Yoshitsugu Nakamura, MD, PhD, Department of Cardiovascular Surgery, Chibanishi General Hospital, 107-1 Kanegasaku, Matsudo, Chiba 270-2251, Japan. email: ystgnkmr@gmail.com
All rights are reserved to the Japanese Circulation Society. For permissions, please email: cj@j-circ.or.jp
ISSN-1346-9843

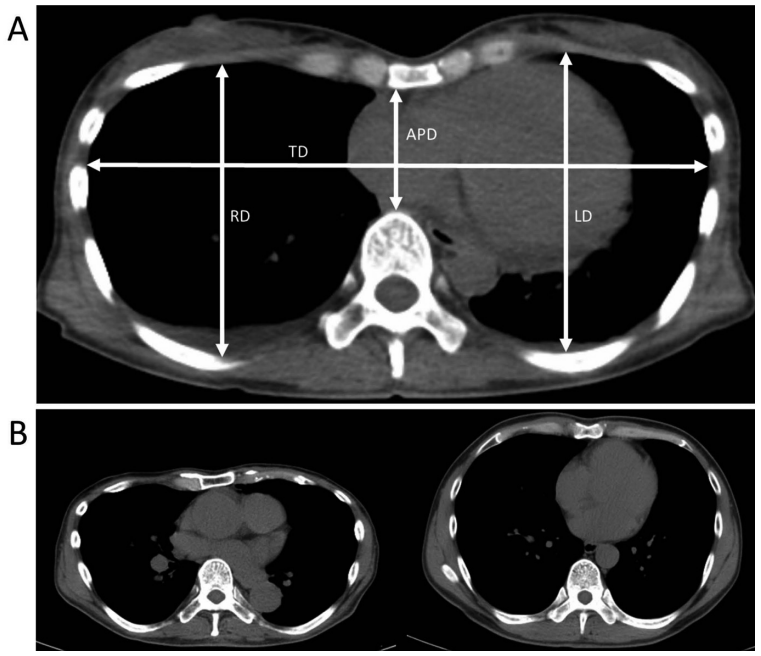

Figure 1. (**A**) Anatomical measurements of the thoracic cavity on preoperative computed tomography scans in patients undergoing minimally invasive mitral valve surgery via a right minithoracotomy. The Haller index (HI) is calculated as the ratio of transverse thoracic diameter (TD) to anteroposterior diameter (APD) between the sternum and vertebra. LD, APD of the left hemithorax; RD, APD of the right hemithorax. (**B**) A narrow chest (HI=4.17; **Left**) and a normal chest (HI=2.20; **Right**).

racic deformity, was calculated as follows:[7,8]

$$AI = 1 - LD/RD$$

To assess the asymmetry of the thoracic cavity, we compared the size of the right and left hemithoraxes using the AI; an AI less than −0.05 indicated a significantly larger left than right hemithorax, an AI greater than 0.05 indicated a significantly larger right than left hemithorax, and an AI between −0.05 and 0.05 indicated no significant difference between the right and left hemithoraxes.[7,8] The CT measurements were conducted at the level of the lower end of the sternum, where the sensitivity of the HI is the highest according to the report of Sesia et al for the accurate assessment of pectus excavatum.[8] CT measurements and indices are shown in **Figure 1**.

The 206 patients were divided into 2 groups according to the HI, one with a narrow chest (Group N; HI >2.5; n=53) and the other with a normal chest (control group [Group C]; HI ≤2.5; n=153).[4,9–12] We then compared the preoperative patient characteristics, CT measurements, operation time, and early postoperative outcomes between the 2 groups. In addition, to evaluate the effects of anatomical measurements on procedural time during mitral valve surgery, we performed regression analysis to examine correlations between CT measurements and aortic cross-clamp time (ACCT) in patients who underwent isolated mitral valve surgery (n=133).

Operative Technique

The operative technique has been described in detail previously in a report on the early and mid-term outcomes of minimally invasive mitral valve repair via a right minithoracotomy.[13] Cardiopulmonary bypass was established using a right common femoral arteriovenous bypass. In cases of severe calcification or thrombus in the aorta, iliac, or femoral arteries, the right axillary artery was cannulated. Surgery was then performed with direct vision via a right lateral minithoracotomy through the 4th intercostal space, with an incision that was 5–6 cm long and 2–3 cm lateral to the nipple. Valve repair was the first choice of treatment for patients with degenerative mitral valve disease. As an alternative, prosthetic valve replacement was chosen in patients in whom valve repair was difficult and in those with severe calcifications of the mitral valve annulus or leaflet. Valve repair was performed using a combination of complete or partial ring annuloplasty, quadrangular/triangular resection, folding plasty, edge-to-edge repair, and neochord placement techniques.

Data Collection

A contrast CT scan (256-row multislice helical scan) of the chest and pelvis was performed for preoperative evaluation in all patients except those with severe renal dysfunction. The aforementioned anatomical measurements were made on preoperative CT scans and verified by 2 authors. Other data on preoperative patient characteristics, operation time, and postoperative outcomes were extracted from the medical records and the Department of Cardiovascular Surgery's database.

Statistical Analysis

Categorical variables are summarized as frequencies and percentages, whereas continuous variables are presented as the mean±SD or median with interquartile range, depending on distribution. Groups were compared using Pearson's Chi-squared test or Fisher's exact test for categorical variables and the Mann-Whitney U test or Student's t-test for continuous variables.

Surgical death was defined as death within 30 days after surgery. Re-exploration was defined as the requirement for median conversion intraoperatively, or surgery due to thoracic bleeding or mitral valve failure within 30 days postoperatively. Respiratory failure was defined as the requirement for a ventilator for a minimum of 72 h or the

Table 1. Demographics of Patients Who Underwent Minimally Invasive Mitral Valve Surgery via a Right Minithoracotomy

	Group N (HI >2.5; n=53)	Group C (HI ≤2.5; n=153)	P value
Age (years)			0.002
Mean±SD	61.3±14.4	68.7±12.8	
Range	24–83	20–91	
Male sex	30 (56.6)	86 (56.2)	0.96
Height (cm)	163.2±9.2	160.0±10.6	0.038
BSA (m^2)	1.55±0.17	1.55±0.21	0.87
Etiology of mitral valve dysfunction			
Degenerative	35 (66.0)	90 (58.8)	0.42
Barlow's disease	3 (5.4)	4 (2.3)	0.37
Rheumatic	5 (9.4)	18 (11.8)	0.80
Infective endocarditis	7 (13.2)	8 (5.2)	0.067
Functional	10 (18.9)	41 (26.8)	0.27
Atrial fibrillation	13 (24.5)	36 (23.5)	0.88
Cardiovascular risk factors			
Hypertension	24 (45.3)	76 (49.7)	0.58
Diabetes	5 (9.4)	26 (17.0)	0.26
Chronic renal dysfunction	9 (17.0)	40 (26.1)	0.18
Hemodialysis	0 (0.0)	2 (1.3)	1.00
COPD	2 (3.8)	8 (5.2)	1.00
Previous cardiac surgery	3 (5.7)	15 (9.8)	0.57
Emergency status	1 (1.9)	4 (2.6)	1.00
EuroSCORE II (%)	2.70±3.45	3.08±3.33	0.30
Preoperative echocardiography			
LAD (mm)	42.1±9.0	46.2±10.2	0.015
LVDD (mm)	52.6±7.2	54.1±7.2	0.17
LVEF (%)	67.4±8.3	64.1±11.3	0.065

Unless indicated otherwise, data are given as the mean±SD or n (%). BSA, body surface area; COPD, chronic obstructive pulmonary disease; Group C, normal chest; Group N, narrow chest; HI, Haller index; LAD, left atrial diameter; LVDD, left ventricular diastolic diameter; LVEF, left ventricular ejection fraction.

occurrence of postoperative pneumonia.

Regression analysis was conducted to examine the correlations between CT measurements and ACCT. To streamline the analysis and reduce the influence of confounding factors on ACCT, regression analysis was only performed in patients who underwent isolated mitral valve surgery.

Statistical significance was set at $P<0.05$. All statistical analyses were performed using JMP version 15 (SAS Institute Inc., Cary, NC, USA).

Results

Patient Characteristics

The demographic characteristics of patients are presented in **Table 1**. The mean age differed significantly between Groups N and C (61.3±14.4 vs. 68.7±12.8 years, respectively; P=0.002). Men comprised 56.6% and 56.2% of patients in Groups N and C, respectively (P=0.96). Mean height differed significantly between Groups N and C (163.2±9.2 vs. 160.0±10.6 cm, respectively; P=0.038). There was no significant difference in body surface area between the 2 group (1.55±0.17 vs. 1.55±0.21 m^2 in Groups N and C, respectively; P=0.87).

The etiologies of mitral valve dysfunction were as follows: degenerative mitral regurgitation (MR) in 35 (66.0%) and 90 (58.8%) patients in Groups N and C, respectively (P=0.42); rheumatic mitral stenosis in 5 (9.4%) and 18 (11.8%) patients in Groups N and C, respectively (P=0.80); infective endocarditis in 7 (13.2%) and 8 (5.2%) patients in Groups N and C, respectively (P=0.067); and functional MR in 10 (18.9%) and 41 (26.8%) patients in Groups N and C, respectively (P=0.27). Barlow's disease was seen in 3 (5.4%) patients in Group N and in 4 (2.3%) patients in Group C (P=0.37). There was no significant difference in the etiologies of mitral valve dysfunction between the groups. Atrial fibrillation (AF) was seen in 13 (24.5%) patients in Group N and in 36 (23.5%) in Group C (P=0.88).

Comorbidities included hypertension (45.3% vs. 49.7% in Groups N and C, respectively; P=0.58), diabetes (9.4% vs. 17.0% in Groups N and C, respectively; P=0.26), chronic renal dysfunction (17.0% vs. 26.1% in Groups N and C, respectively; P=0.18), hemodialysis (0.00% vs. 1.3% in Groups N and C, respectively; P=1.00), and chronic obstructive pulmonary disease (3.8% vs. 5.2% in Groups N and C, respectively; P=1.00). Three (5.7%) patients in Group N and 15 (9.8%) patients in Group C had a history of cardiac surgery (P=0.57). One (1.9%) patient in Group N and 4 (2.6%) patients in Group C underwent emergency surgery (P=1.00). There was no significant difference in EuroSCORE II between Groups N and C (2.70±3.45 vs. 3.08±3.33, respectively; P=0.30).

Table 2. Anatomical Measurements of the Thoracic Cavity on Computed Tomography Scans in Patients Who Underwent Minimally Invasive Mitral Valve Surgery via a Right Minithoracotomy

	Group N (HI >2.5; n=53)	Group C (HI ≤2.5; n=153)	P value
APD (mm)	89.4±10.9	114.3±13.1	<0.001
TD (mm)	251.5±19.5	240.3±21.3	0.002
RD (mm)	152.5±14.8	172.5±15.0	<0.001
LD (mm)	155.0±14.4	172.4±14.0	<0.001
HI	2.84±0.33	2.12±0.23	<0.001
Asymmetry index			
−0.05 to 0.05 (normal range)	43 (81.1)	139 (90.0)	0.080
<−0.05 (larger left hemithorax)	8 (15.1)	8 (5.2)	0.034
>0.05 (larger right hemithorax)	2 (3.8)	6 (3.9)	1.00

Unless indicated otherwise, data are given as the mean±SD or n (%). APD, anteroposterior diameter between the sternum and vertebra; LD, anteroposterior diameter of the left hemithorax; Group C, normal chest; Group N, narrow chest; HI, Haller index; RD, anteroposterior diameter of the right hemithorax; TD, transverse thoracic diameter.

Table 3. Operative Procedures of Minimally Invasive Mitral Valve Surgery via a Right Minithoracotomy

	Group N (HI >2.5; n=53)	Group C (HI ≤2.5; n=153)	P value
Arterial cannulation			
Femoral	44 (83.0)	104 (68.0)	0.050
Right axillary	9 (17.0)	50 (32.7)	0.034
Procedure			
MV repair	39 (73.9)	113 (73.9)	0.97
MVR	14 (26.4)	40 (26.1)	–
TAP	12 (22.6)	24 (15.7)	0.25
Maze	14 (26.4)	30 (19.6)	0.30
LAAC	5 (9.8)	19 (12.3)	0.80
OP time (min)	220.1±50.7	227.8±54.6	0.28
ACCT (min)	118.7±50.7	105.8±30.6	0.047

Unless indicated otherwise, data are given as the mean±SD or n (%). ACCT, aortic cross clamp time; Group C, normal chest; Group N, narrow chest; HI, Haller index; LAAC, left atrial appendage closure; MV, mitral valve; MVR, mitral valve replacement; OP, operative; TAP, tricuspid annuloplasty.

CT Scans of the Thoracic Cavity

CT measurements and indices of thoracic deformities are presented in **Table 2**. There were significant differences between Groups N and C in mean APD (89.4±10.9 vs. 114.3±13.1 mm, respectively; P<0.001), mean TD (251.5±19.5 vs. 240.3±21.3 mm, respectively; P=0.002), mean RD (152.5±14.8 vs. 172.5±15.0 mm, respectively; P<0.001), mean LD (155.0±14.4 vs. 172.4±14.0 mm, respectively; P<0.001), and mean HI (2.84±0.33 vs. 2.12±0.23, respectively; P<0.001). There was no significant difference in the proportion of patients with a normal AI between Groups N and C (81.1% vs. 90.9%, respectively; P=0.080), but the proportion of patients with an AI less than −0.05 was significantly greater in Group N (15.1% vs. 5.2%; P=0.034).

Preoperative Echocardiography

All patients underwent preoperative echocardiographic measurement of cardiac dimensions (**Table 1**). Mean left atrial diameter differed significantly between Groups N and C (42.1±9.0 vs. 46.2±10.2 mm, respectively; P=0.015), but there was no significant difference between the 2 groups in mean left ventricular end-diastolic diameter (52.6±7.2 vs. 54.1±7.2 mm, respectively; P=0.17) or mean left ventricular ejection fraction (67.4%±8.3 vs. 64.1%±11.3, respectively; P=0.065).

Operative Procedures and Operation Time

The operative procedures and operation times are presented in **Table 3**. Femoral artery cannulation was performed in a significantly higher proportion of patients in Group N than Group C (44 [83.0%] vs. 104 [68.0%], respectively; P=0.050), whereas right axillary artery cannulation was performed in a significantly lower proportion of patients in Group N (9 [17.0%] vs. 50 [32.7%]; P=0.034). MV repair and replacement were performed in 39 (73.9%) and 14 (26.4%) patients, respectively, in Group N, and in 113 (73.9%) and 40 (26.1%), respectively, patients in Group C. There was no significant difference between the 2 groups in terms of the mitral valve procedure (P=0.97). Similarly, there was no significant difference in conversion from valve repair to prosthetic valve replacement between Groups N and C (2 [3.8%] vs. 2 [1.3%], respectively; P=0.27). Concomitant procedures included tricuspid annuloplasty (TAP), the maze procedure, left atrial appendage closure, and patent foramen ovale and atrial septal defect closure. There were no significant differences between Groups N and C in TAP (12 [22.6%] vs. 24 [15.7%], respectively; P=0.25, maze procedure (14 [26.4%] vs. 30 [19.6%], respectively; P=0.30), or

Table 4. Early Postoperative Outcomes Following Minimally Invasive Mitral Valve Surgery via a Right Minithoracotomy

	Group N (HI >2.5; n=53)	Group C (HI ≤2.5; n=153)	P value
Operative death	0 (0.0)	1 (0.7)	1.00
Re-exploration	1 (1.9)	2 (1)	1.00
Symptomatic cerebral infarction	0 (0.0)	0 (0.0)	–
Respiratory failure	1 (1.9)	3 (2.0)	1.00
Surgical site infection	0 (0.0)	2 (1.3)	1.00

Unless indicated otherwise, data are given as n (%). Group C, normal chest; Group N, narrow chest; HI, Haller index.

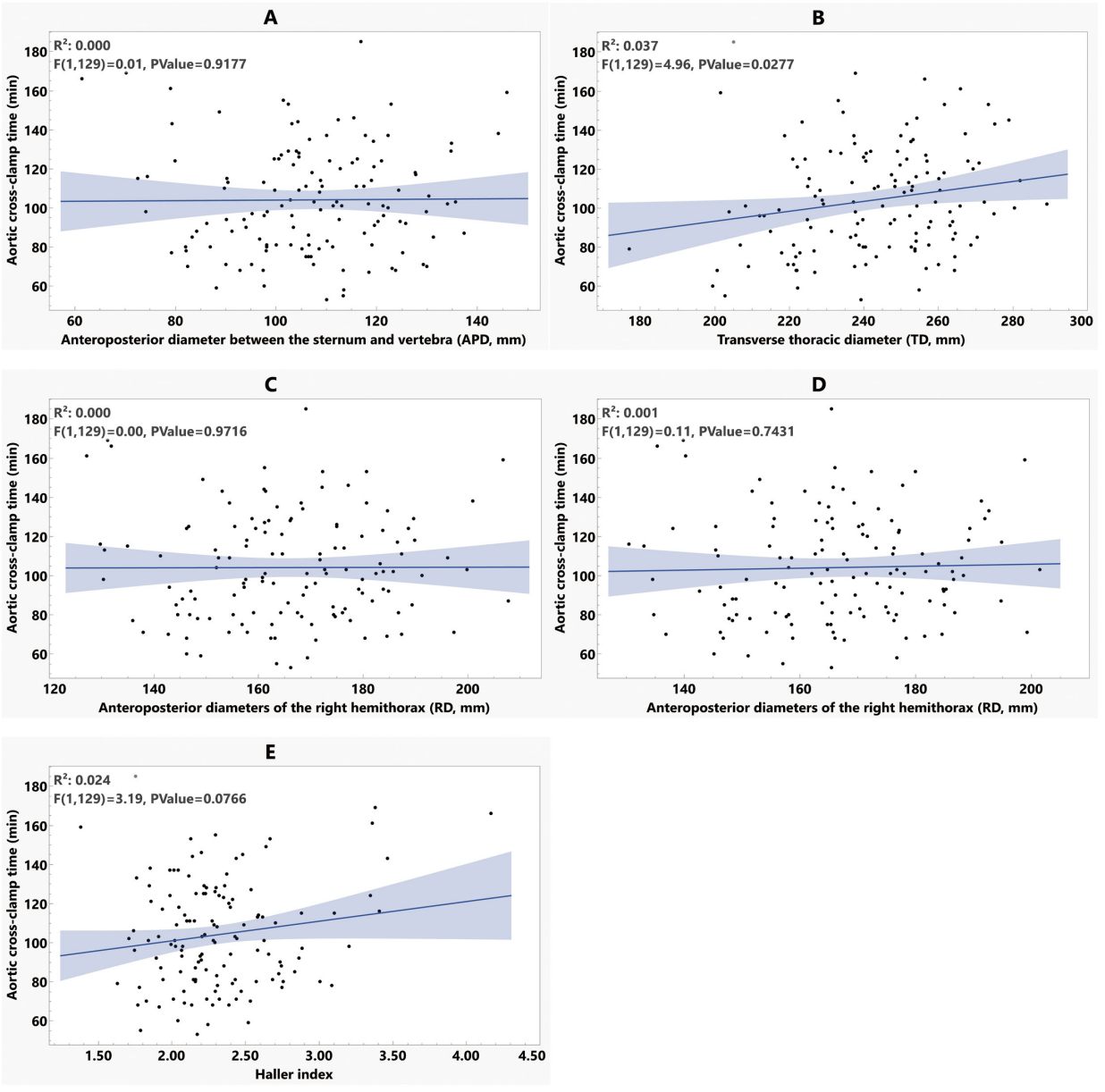

Figure 2. Correlation between aortic cross-clamp time during minimally invasive mitral valve surgery via a right mini-thoracotomy and computed tomography measurements of the thoracic cavity: (**A**) anteroposterior diameter (APD) between the sternum and vertebra; (**B**) transverse thoracic diameter; (**C**) APD of the right hemithorax; (**D**) APD of the left hemithorax; and (**E**) Haller index.

left atrial appendage closure (5 (9.8%) vs. 19 (12.3%), respectively; P=0.80). Surgery in 1 patient in Group N required conversion to median sternotomy because of thoracic bleeding.

There was no significant difference in mean total operation time between Groups N and C (220.1±50.7 vs. 227.8±54.6 min, respectively; P=0.28; **Table 3**). However, mean ACCT was significantly longer in Group N than Group C (118.7±50.7 vs. 105.8±30.6 min, respectively; P=0.047; **Table 3**).

Early Postoperative Outcomes

Postoperative outcomes are presented in **Table 4**. Operative death was observed only in Group C (n=1; 0.7%), with no significant difference between the groups (P=1.00). Re-exploration occurred in 1 (1.9%) patient in Group N and 2 (1.3%) patients in Group C (P=1.00). All re-explorations were prompted by thoracic bleeding, with no valve-related reoperations noted. Median conversion due to bleeding occurred in 1 (0.7%) patient in Group C. Respiratory failure was observed in 1 (1.9%) patient in Group N and 3 (2.0%) patients in Group C, with no significant difference between the 2 groups (P=1.00). Surgical site infection was observed only in Group C (n=2; 1.3%), with no significant difference between the groups (P=1.00). There was no symptomatic cerebral infarction in either of the groups.

Regression Analysis of Correlations Between CT Measurements and ACCT

The correlation between each CT measurement and ACCT was evaluated using regression analysis in 133 patients who underwent isolated mitral valve surgery. The results are shown in **Figure 2**. Analysis showed that there were no significant correlations between APD and ACCT (P=0.92), RD and ACCT (P=0.97), LD and ACCT (P=0.74), or HI and ACCT (P=0.077). However, there was a significant positive correlation between TD and ACCT (R^2=0.037, P=0.028).

Discussion

Sonaglioni et al reported that in patients with mitral valve prolapse, those with a narrow chest had a smaller heart chamber, including left atrial diameter, than those with a normal chest.[14] Although patient characteristics differed between the present study and that of Sonaglioni et al, abnormalities in the thoracic cavity may affect the morphology and size of the heart. Although the size of the left atrium may also be affected by the duration of MR and complications of AF, in the present study there was no significant difference in the prevalence of AF between Groups N and C.

In patients with a narrow chest, the small APD of the thoracic cavity is believed to limit mitral valve exposure[1] and the surgical working space. However, in the present study, although the ACCT was significantly longer in Group N, in which patients had a smaller APD, ACCT was not directly correlated with APD, whereas there was a significant positive correlation between TD and ACCT. This suggests that during MIMVS, the time required for surgical maneuvers is more affected and prolonged by the greater distance from the chest wall to the heart or mitral valve than by the smaller APD of the thoracic cavity. In addition, in pectus excavatum, the heart is displaced leftwards[1,2,9] and there is a greater distance from the chest wall to the valves. In patients with a narrow chest, these findings may help surgeons consider patient selection, especially in the initial phase of MIMVS. Notably, the asymmetry of the thoracic cavity differed between Groups N and C in the present study. Generally, a larger left hemithorax is more common[8] and is frequently observed in patients with a narrow chest. Thus, in these patients, surgical maneuvers may be limited by the relatively narrow right hemithorax, or exposure of the mitral valve may be compromised by the heart dropping into the relatively large left hemithorax. In the present study, the proportion of patients with a significantly larger left hemithorax was approximately 3-fold greater in Group N than Group C, which may have led to the difference in ACCT in the MIMVS group.

In the case of a narrow chest, a more lateral approach may be required.[13] It should be considered that the distance from the incision to the mitral valve tends to be longer in patients with narrow chest and longer TD. Moreover, the orientation of the mitral valve and its position relative to the vertebral body may also affect the surgical exposure; thus, it may be better to evaluate these factors in 3 dimensions. In general, it is believed that minimally invasive cardiac surgery in patients with a longer distance from the incision to the heart is facilitated by endoscopic assistance or the addition of a port. In the present study, all surgeries were performed under direct vision and through the main incision only, although the results may have been different if these options or robotic surgery had been selected.

As a result of following our perfusion criteria,[13] right axillary artery cannulation was performed more frequently in Group C. This may be due to the older age of patients in Group C and the poorer properties of the aorta and iliac arteries, although there was no difference in the incidence of cerebral infarction between the 2 groups.

Early surgical outcomes, including all-cause mortality, re-exploration, and cerebrovascular events, were satisfactory in both groups compared with other reports on mitral valve surgery via a right lateral thoracotomy.[15–19] Therefore, with an experienced surgeon and team, MIMVS may be successfully performed even in patients with a narrow chest.

Study Limitations

This study has several limitations because of its retrospective design and lack of prospective randomization. One of the limitations is the potential for measurement bias. Although the CT measurements were performed and verified by 2 authors, bias could potentially exist because the study was retrospectively designed, and data variability may have been introduced. Another limitation was the potential for selection bias. Patient selection, determination of indications for surgery, and the choice of procedure strongly depend on the surgeon's discretion; therefore, the generalizability of our findings is limited. In addition, mitral valve repair techniques vary according to the etiology and morphology of mitral valve insufficiency; therefore, it may not be appropriate to compare the time required for mitral valve repair. Furthermore, although the percentage of patients who underwent TAP, maze, or other procedures did not differ between the 2 groups, the time required for these procedures varied from case to case, which poses a limitation when comparing ACCTs. Finally, other anatomical measurements not included in the present study may significantly affected the ACCT in

MIMVS via a right minithoracotomy.

Conclusions

Early operative outcomes of MIMVS via a right minithoracotomy in patients with a narrow chest were satisfactory and comparable to those in patients with a normal chest. Patients with mitral valve disease and a narrow chest could have a large transverse TD, which may prolong the ACCT during MIMVS via a right minithoracotomy.

Acknowledgments

The authors thank all surgeons and medical staff of the Chibanishi General Hospital who contributed to this project. I also thank Rino Sawa for help with data management and image editing, as well as her support and encouragement throughout the study.

Sources of Funding

None.

Disclosures

None declared.

Author Contributions

Data curation, investigation, and writing – original draft: S.S.; Conceptualization, project administration, supervision, validation, writing – review and editing: Y.N.; Investigation: T.N., M.K., K. Nakamae, K. Niitsuma, M.U., Y.Y., D.Y., A.F., Y.I., R.T.

IRB Information

This study was approved by the Tokushukai Group Ethics Committee, 2023 (No. TGE01969-025).

Data Availability

The deidentified participant data will be shared on a request basis. Please contact the corresponding author directly to request data sharing. The entire dataset used will be available, including the study protocol. Data will be shared as soon as the Institutional Review Board at Chibanishi General Hospital approves it, and will be available until the end of March, 2034. Data will be shared with anyone wishing to access the data. Any analyses on the data will be approved and data will be shared as Excel file via email.

References

1. Onan B, Bakir I. Robotic mitral valve replacement in pectus excavatum. *J Card Surg* 2016; **31:** 306–308.
2. van der Merwe J, Casselman F, Stockman B, Vermeulen Y, Degrieck I, Van Praet F. Endoscopic atrioventricular valve surgery in adults with difficult-to-access uncorrected congenital chest wall deformities. *Interact Cardiovasc Thorac Surg* 2016; **23:** 851–855.
3. Haller JA Jr, Kramer SS, Lietman SA. Use of CT scans in selection of patients for pectus excavatum surgery: A preliminary report. *J Pediatr Surg* 1987; **22:** 904–906.
4. Kelly RE Jr, Mellins RB, Shamberger RC, Mitchell KK, Lawson ML, Oldham KT, et al. Multicenter study of pectus excavatum, final report: Complications, static/exercise pulmonary function, and anatomic outcomes, final report. *J Am Coll Surg* 2013; **217:** 1080–1089.
5. Ohte N, Ishizu T, Izumi C, Itoh H, Iwanaga S, Okura H, et al. JCS 2021 guideline on the clinical application of echocardiography. *Circ J* 2022; **86:** 2045–2119.
6. Izumi C, Eishi K, Ashihara K, Arita T, Otsuji Y, Kunihara T, et al. JCS/JSCS/JATS/JSVS 2020 guidelines on the management of valvular heart disease. *Circ J* 2020; **84:** 2037–2119.
7. Kilda A, Basevicius A, Barauskas V, Lukosevicius S, Ragaisis D. Radiological assessment of children with pectus excavatum. *Indian J Pediatr* 2007; **74:** 143–147.
8. Sesia SB, Heitzelmann M, Schaedelin S, Magerkurth O, Kocher GJ, Schmid RA, et al. Standardized Haller and asymmetry index combined for a more accurate assessment of pectus excavatum. *Ann Thorac Surg* 2019; **107:** 271–276.
9. Tran NT, Klein LJ, Mounsey PJ, Chung EH, Schwartz JD, Pursell I, et al. Lone atrial fibrillation is associated with pectus excavatum. *Heart Rhythm* 2013; **10:** 1263–1269.
10. Shaalan AM, Kasb I, Elwakeel EE, Elkamali YA. Outcome of surgical repair of pectus excavatum in adults. *J Cardiothorac Surg* 2017; **12:** 72.
11. Fonkalsrud EW. 912 open pectus excavatum repairs: Changing trends, lessons learned: One surgeon's experience. *World J Surg* 2009; **33:** 180–190.
12. Kelly RE Jr. Pectus excavatum: Historical background, clinical picture, preoperative evaluation and criteria for operation. *Semin Pediatr Surg* 2008; **17:** 181–193.
13. Nakayama T, Nakamura Y, Yasumoto Y, Yoshiyama D, Kuroda M, Nishijima S, et al. Early and mid-term outcomes of minimally invasive mitral valve repair via right mini-thoracotomy: 5-year experience with 129 consecutive patients. *Gen Thorac Cardiovasc Surg* 2021; **69:** 1174–1184.
14. Sonaglioni A, Nicolosi GL, Lombardo M, Gensini GF, Ambrosio G. Influence of chest conformation on myocardial strain parameters in healthy subjects with mitral valve prolapse. *Int J Cardiovasc Imaging* 2021; **37:** 1009–1022.
15. Al Shamry A, Jegaden M, Ashafy S, Eker A, Jegaden O. Minithoracotomy versus sternotomy in mitral valve surgery: Meta-analysis from recent matched and randomized studies. *J Cardiothorac Surg* 2023; **18:** 101.
16. Akowuah EF, Maier RH, Hancock HC, Kharatikoopaei E, Vale L, Fernandez-Garcia C, et al. Minithoracotomy vs conventional sternotomy for mitral valve repair: A randomized clinical trial. *JAMA* 2023; **329:** 1957–1966.
17. Sündermann SH, Sromicki J, Rodriguez Cetina Biefer H, Seifert B, Holubec T, Falk V, et al. Mitral valve surgery: Right lateral minithoracotomy or sternotomy? A systematic review and meta-analysis. *J Thorac Cardiovasc Surg* 2014; **148:** 1989–1995.e4.
18. Falk V, Cheng DC, Martin J, Diegeler A, Folliguet TA, Nifong LW, et al. Minimally invasive versus open mitral valve surgery: A consensus statement of the International Society of Minimally Invasive Coronary Surgery (ISMICS) 2010. *Innovations (Phila)* 2011; **6:** 66–76.
19. Sakaguchi T. Minimally invasive mitral valve surgery through a right mini-thoracotomy. *Gen Thorac Cardiovasc Surg* 2016; **64:** 699–706.