Robotic myxoma resection using an ultrasonic aspirator system

Check for updates

Yoshitsugu Nakamura, MD, PhD, Miho Kuroda, MD, Yuto Yasumoto, MD, and Taisuke Nakayama, MD, PhD, Chiba, Japan

From the Department of Cardiovascular Surgery, Chibanishi General Hospital, Chiba, Japan.

IRB No. 002482; August 22, 2024.
The 3 patients provided informed written consent for publication of study data.
Received for publication Sept 12, 2024; revisions received Sept 27, 2024; accepted for publication Oct 1, 2024; available ahead of print Oct 16, 2024.

Address for reprints: Yoshitsugu Nakamura, MD, PhD, Department of Cardiovascular Surgery, Chibanishi General Hospital, 107-1 Kanegasaku, Matsudo, Chiba 270-2251, Japan (E-mail: ystgnkmr@gmail.com).

JTCVS Techniques 2025;29:100-2
2666-2507

Copyright © 2024 The Author(s). Published by Elsevier Inc. on behalf of The American Association for Thoracic Surgery. This is an open access article under the CC BY-NC-ND license (http://creativecommons.org/licenses/by-nc-nd/4.0/).

https://doi.org/10.1016/j.xjtc.2024.10.005

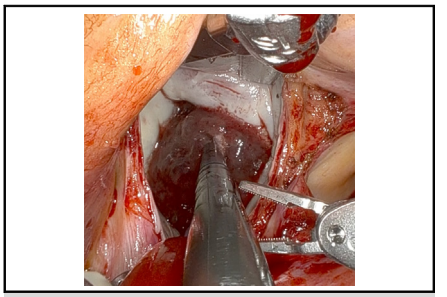

The myxoma was debulked with an ultrasonic aspirator system in robotic myxoma resection.

CENTRAL MESSAGE

Using an ultrasonic aspirator system for robotic myxoma resection is simple, safe, and reliable.

Video clip is available online.

Performing myxoma resection through right mini-thoracotomy is reported to be less invasive and more efficient, with or without robot-assistance.[1-3] Left atrial myxomas can be seen directly through right-side left atriotomy, but because myxomas are gelatinous and friable, they are easily damaged during surgical manipulation, potentially causing embolism or metastasis in the pulmonary veins or left ventricle. Therefore, resection of the tumor and its attachment to the endocardium as a single mass is recommended. However, this is difficult for large myxomas, especially when using robot assistance and small skin incisions. We report a novel technique in robot-assisted myxoma resection that uses the Sonopet iQ Ultrasonic Aspirator System (Stryker) (Figure 1, *A*) (institutional review board No. 002482; August 22, 2024). The 3 patients provided informed written consent for publication of study data.

SURGICAL TECHNIQUE

Under general anesthesia using single-lung ventilation, a 3-cm working port also used for the robotic camera port was created in the fourth intercostal space on the left anterior axillary line. See Video 1. The left- and right-hand ports and robotic arms were placed in the third and sixth intercostal spaces, respectively. A retractor port was placed through an areola incision. Cardiopulmonary bypass was established through the right femoral artery and femoral and jugular vein cannulation. Vacuum assistance was used for venous drainage (40-60 mm Hg). The ascending aorta was crossclamped using a Cygnet flexible clamp (Vitalitec Inc) with antegrade crystalloid cardioplegia delivery.

The myxoma was exposed with a robotic dynamic retractor through right side left atriotomy (Figure 2, *A*). A flexible sucker was inserted into the left atrium to achieve a bloodless field. A small sample of the myxoma was resected for immediate pathology confirmation. The patient-site surgeon inserted the Sonopet through the working port, positioning it against the myxoma with robotic assistance (Figure 1, *B*). The Sonopet's outputs were set to 50% ultrasound power, 70% suction pressure, and 15 mL/minute irrigation rate. The myxoma was gradually fragmented and aspirated from the camera side. After most of the myxoma was debulked, a roughly 1-cm core of the elastic hard tumor core remained (Figure 2, *B*) attached to the left atrial endocardium. The entire thickness of the left atrial endocardium at the myxoma attachment site was excised with a 5-mm margin. If there was concern about the margin size, an additional circular excision was made around the resected area. When removing the excised myxoma, we used the EndoCatch specimen retrieval pouch (Medtronic) to prevent accidental dropping in the left atrium or the left pleural cavity. However, its use is based on surgeon's preference and is not essential. If the atrial



FIGURE 1. A, Sonopet iQ Ultrasonic Aspirator System 205 mm soft tissue tip (Stryker). B, Intraoperative photograph, a patient-site surgeon applies Sonopet through a 3-cm working port.

septum of the attachment area was thin or communication arose with the right atrium, the hole was closed with 4-0 monofilament sutures. Because vacuum-assisted venous drainage is being used, small communications are not an issue. However, if a large communication occurs, there is a risk of air block or hypercapnia. Therefore, it is advisable to snare the superior vena cava and inferior vena cava in advance when the atrial septum of the attachment site is large and thin like the foramen ovale. The atriotomy was closed with continuous sutures. The crossclamp was released, transesophageal echocardiography was performed, and cardiopulmonary bypass was terminated.

We employed this method in 3 cases of cardiac myxomas, all of which had favorable outcomes. Average crossclamp time and cardiopulmonary bypass time were 58 and 109 minutes, respectively.

DISCUSSION

The advantages of the technique described are its simplicity; the tumor is not grasped, reducing the risk of leaving parts behind; the endocardial attachment site becomes visible after aspiration, leading to adequate resection; and the small skin incision sites remain small.

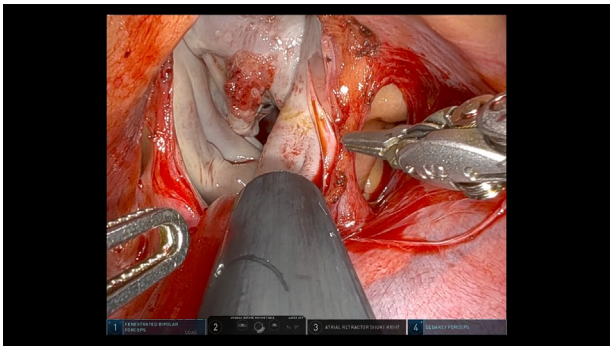

VIDEO 1. Intraoperative robotic endoscopic video. 2× speed. Video available at: https://www.jtcvs.org/article/S2666-2507(24)00437-1/fulltext.

Sonopet Mechanism and Application

Sonopet generates ultrasonic vibrations creating longitudinal and torsional forces. The handpiece of the device provides simultaneous irrigation and suction. Sonopet has been used in neurosurgery, liver, and orthopedic surgery for aspirating and removing tumors safely for more than 20 years,[4,5] but in cardiac surgery it has been limited to removal of calcifications from the aortic valve during aortic valve replacement surgery. We know of no reports using Sonopet for cardiac tumors.

Output levels can be matched to tumor density, allowing for efficient tumor fragmentation and aspiration while preserving surrounding tissues, which have higher density. We optimized our Sonopet output settings based on consultation with the manufacturer and intraoperative adjustments during our 3 cases. The large, soft outer portion of the myxoma was easily fragmented and aspirated at this setting, whereas the firm and elastic core was harder to fragment. Instead, it was excised robotically with the left atrial endocardium was attached. The mitral valve leaflet and left atrial endocardium are not damaged by brief contact with the Sonopet, but there is a risk of injury if contact is sustained for more than a few seconds. Therefore, it is necessary to apply the Sonopet while continuously monitoring its placement with the robotic camera.

Considerations for Robot-Assisted Tumor Resection

In robot-assisted left atrial tumor resections, the camera typically sees only the front of large tumors; its attachment site is hidden. As the myxoma is aspirated, the left atrial wall becomes visible. By the time only the core remains, the attachment site is clearly visible, allowing for safe and secure resection of the remaining tumor and endocardium.

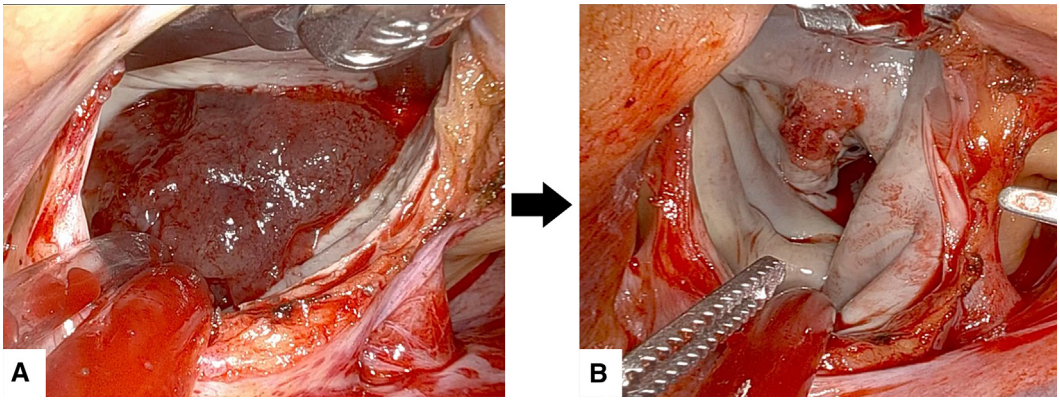

FIGURE 2. A, Myxoma before aspiration with Sonopet iQ Ultrasonic Aspirator System (Stryker). B, Only the core of the myxoma remains after aspiration.

CONCLUSIONS

Using Sonopet for robotic resection of cardiac myxomas is simple, safe, and reliable.

Conflict of Interest Statement

The authors reported no conflicts of interest.

The *Journal* policy requires editors and reviewers to disclose conflicts of interest and to decline handling or reviewing manuscripts for which they may have a conflict of interest. The editors and reviewers of this article have no conflicts of interest.

References

1. Dan HQ, Le HT, Dinh LN. Endoscopic port access resection of left atrial myxoma: clinical outcomes and a single surgeon's learning curve experience. *J Thorac Cardiovasc Surg Tech*. 2024;23:52-62.
2. Rosen JL, Yost CC, Wong DH, et al. Routine endoscopic robotic cardiac tumor resection using an 8-mm working port and percutaneous cannulation. *J Card Surg*. 2022;37:4803-4807.
3. Gao C, Yang M, Wang G, et al. Excision of atrial myxoma using robotic technology. *J Thorac Cardiovas Surg*. 2010;139:1282-1285.
4. Ijiri A, Yoshiki K, Tsuboi S, Shimazaki H, Akiyoshi H, Nakade T. Surgical resection of twenty-three cases of brain menigioma. *J Vet Med Sci*. 2014;76:331-338.
5. Nakagawa H, Kim SD, Mizuno J, Ohara Y, Ito K. Technical advantages of an ultrasonic bone curette in spinal surgery. *J Neuro Spine*. 2005;2:431.